

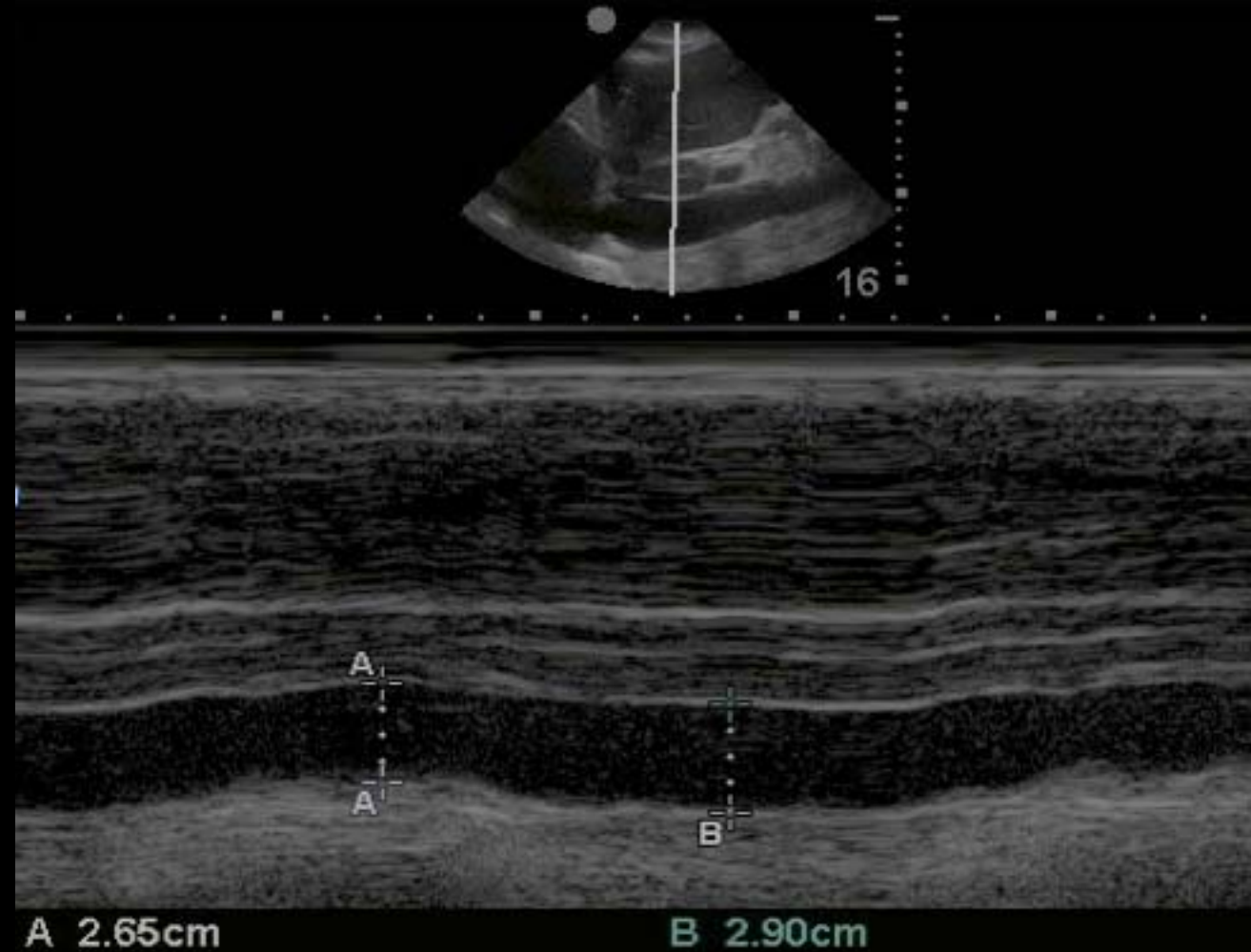# JB Critical Care Ultrasound Course

## MCQ

Choose the ONE best answer for each question

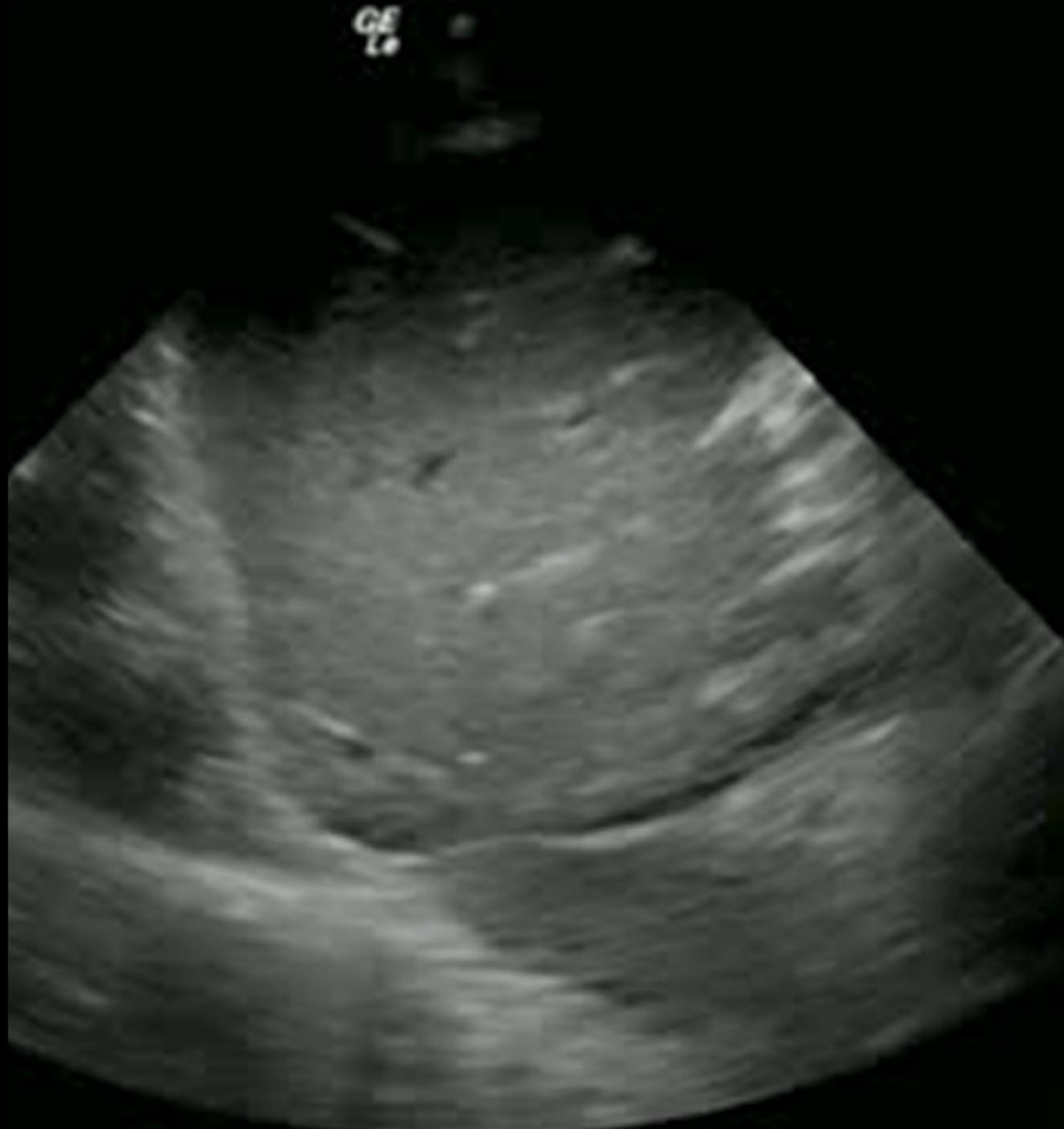# 1. This shocked patient is most likely:

- a) 'Dry'
- b) Euvolaemic
- c) 'Wet'



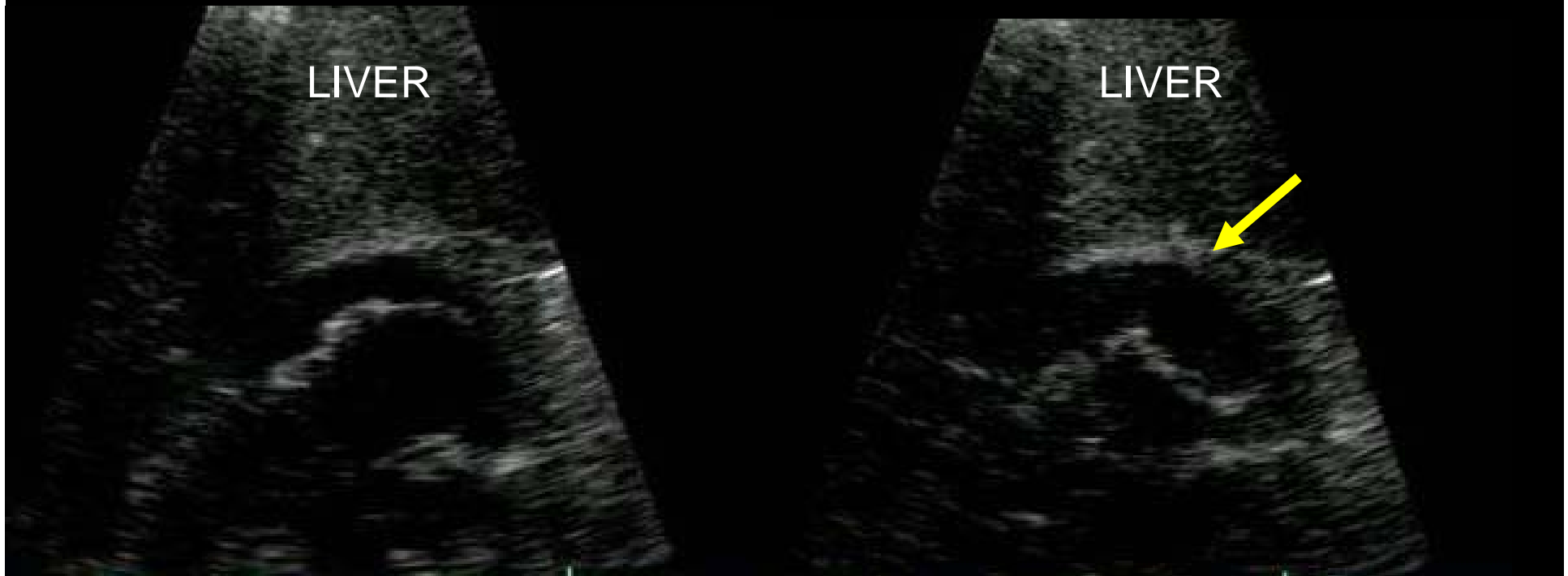
2. This shocked patient is most likely:

- a) 'Dry'
- b) Euvolaemic
- c) 'Wet'



### 3. This subcostal image demonstrates:

- a. No pericardial effusion
- b. Pericardial effusion, likely insignificant
- c. Pericardial effusion, likely significant
- d. Need more information



## 4. Regarding pericardial fluid:

- a) Fluid seen only in systole is usually significant
- b) Impaired left LV filling is an early sign of significant pericardial effusion
- c) The true diagnosis of tamponade is clinical
- d) All of the above are true

5. It is difficult to measure right ventricular function because:

- a) RV shape is unusual
- b) RV is obscured by the sternum
- c) RV is in the near field
- d) RV contracts differently to the LV
- e) All of the above