

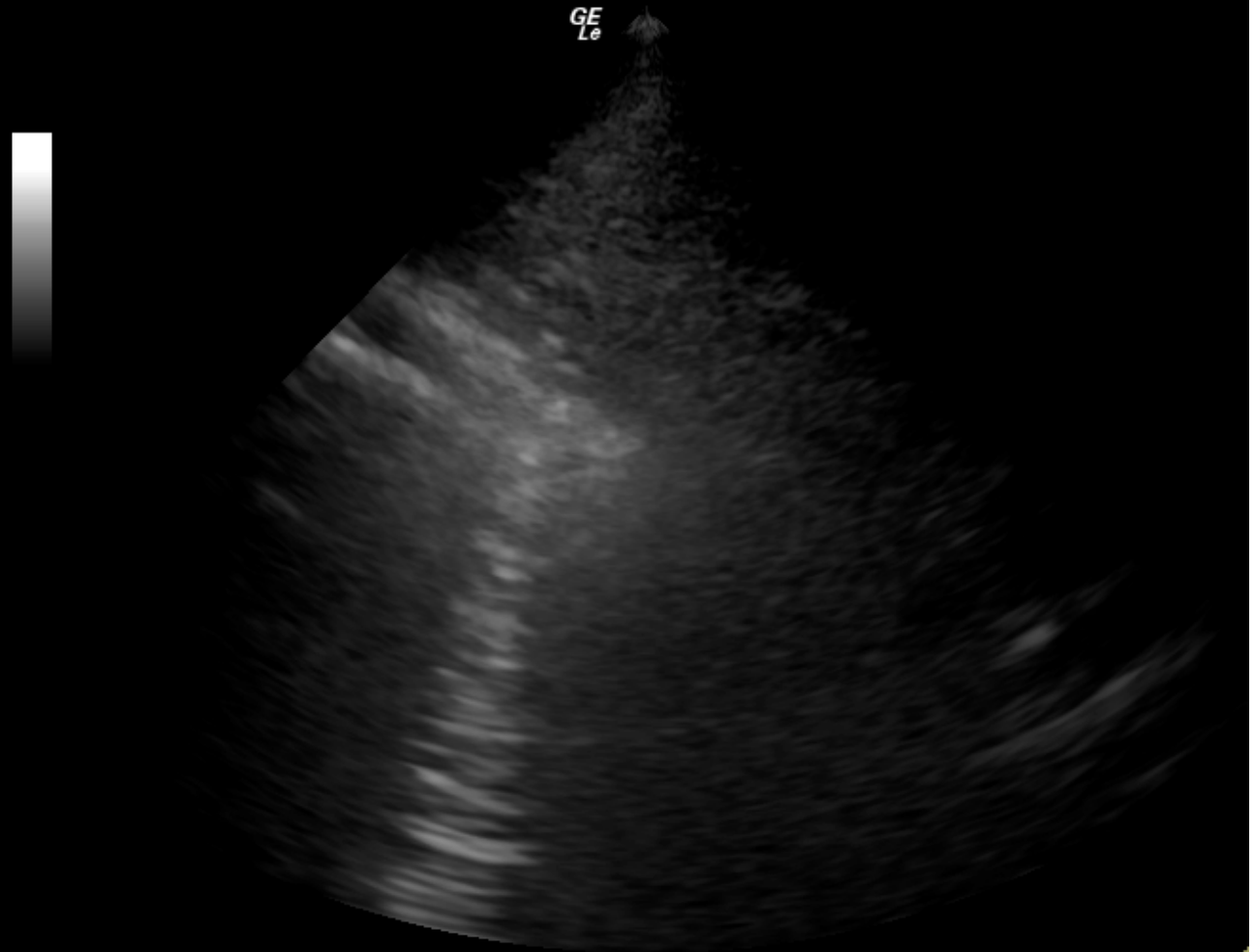
# JB Critical Care Ultrasound Course

## MCQ

Choose the ONE best answer for each question

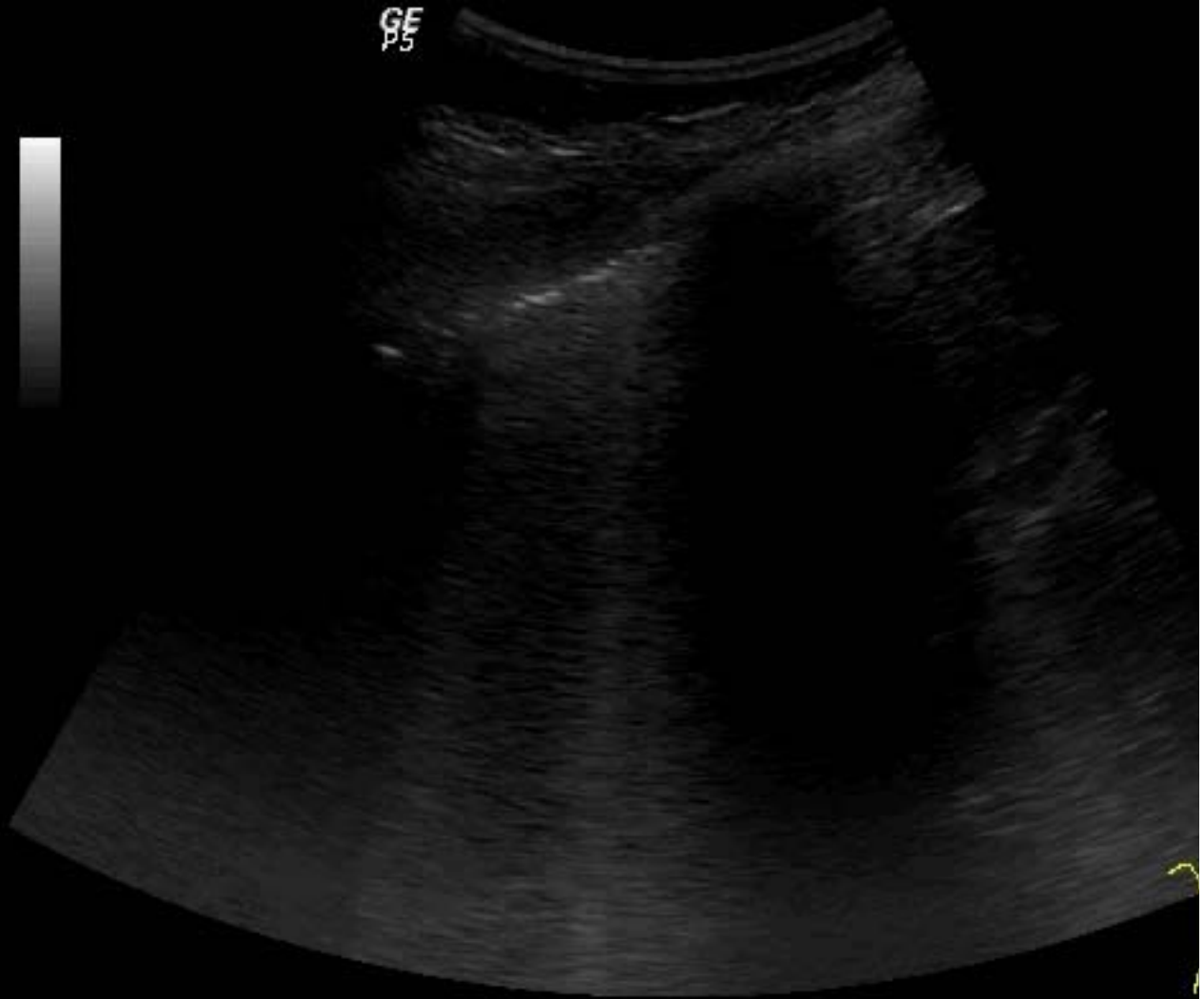
# 1. This lung window demonstrates:

- a) A line
- b) B line
- c) Z line
- d) Need more information



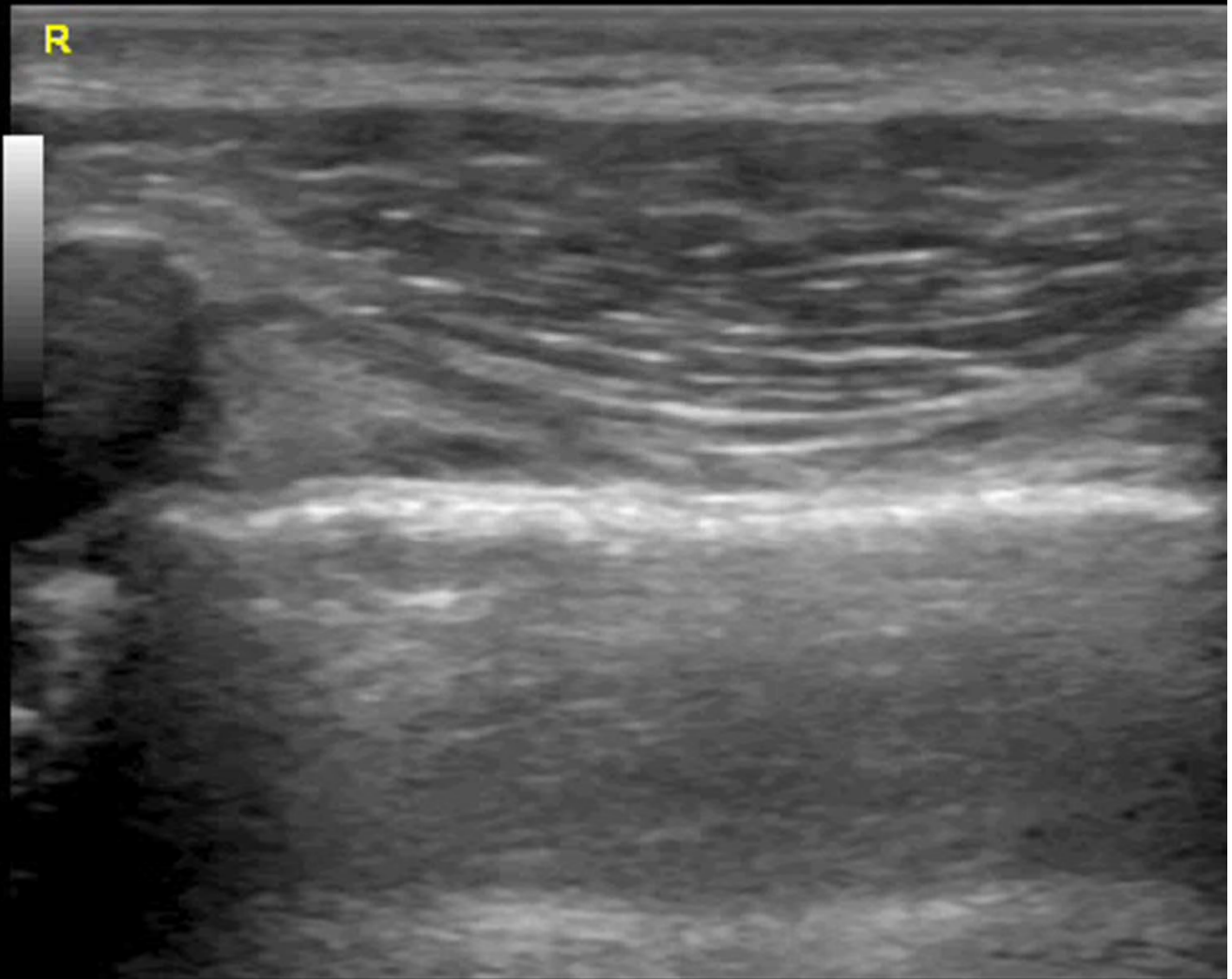
## 2. This US image is consistent with

- a) Pulmonary oedema
- b) Pneumonia
- c) Fibrosis
- d) All of the above



### 3. This US loop demonstrates:

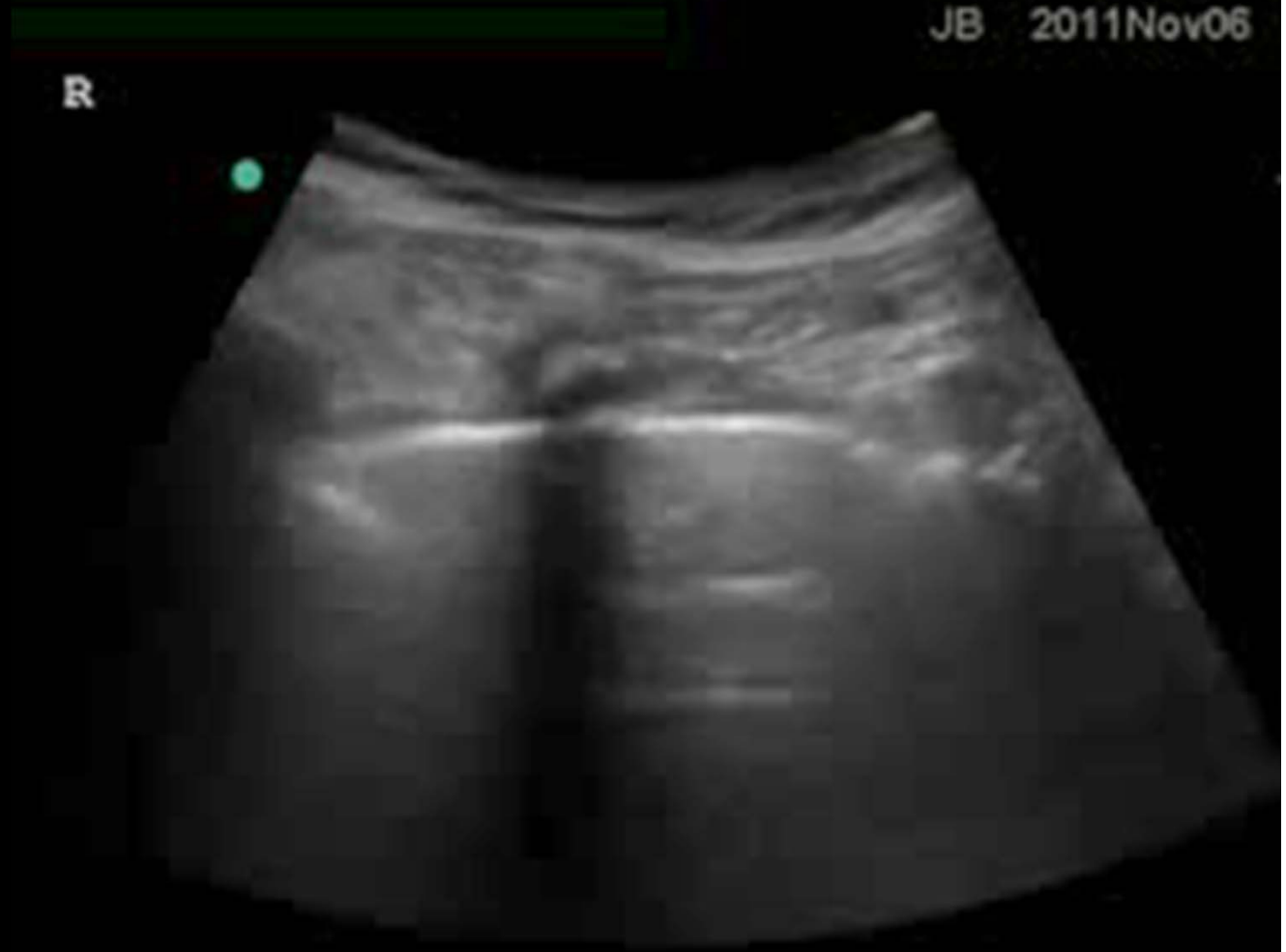- a) Normal lung
- b) Pneumothorax
- c) Need more information



4. Breathless patient. This US loop is consistent with:

JB 2011Nov06

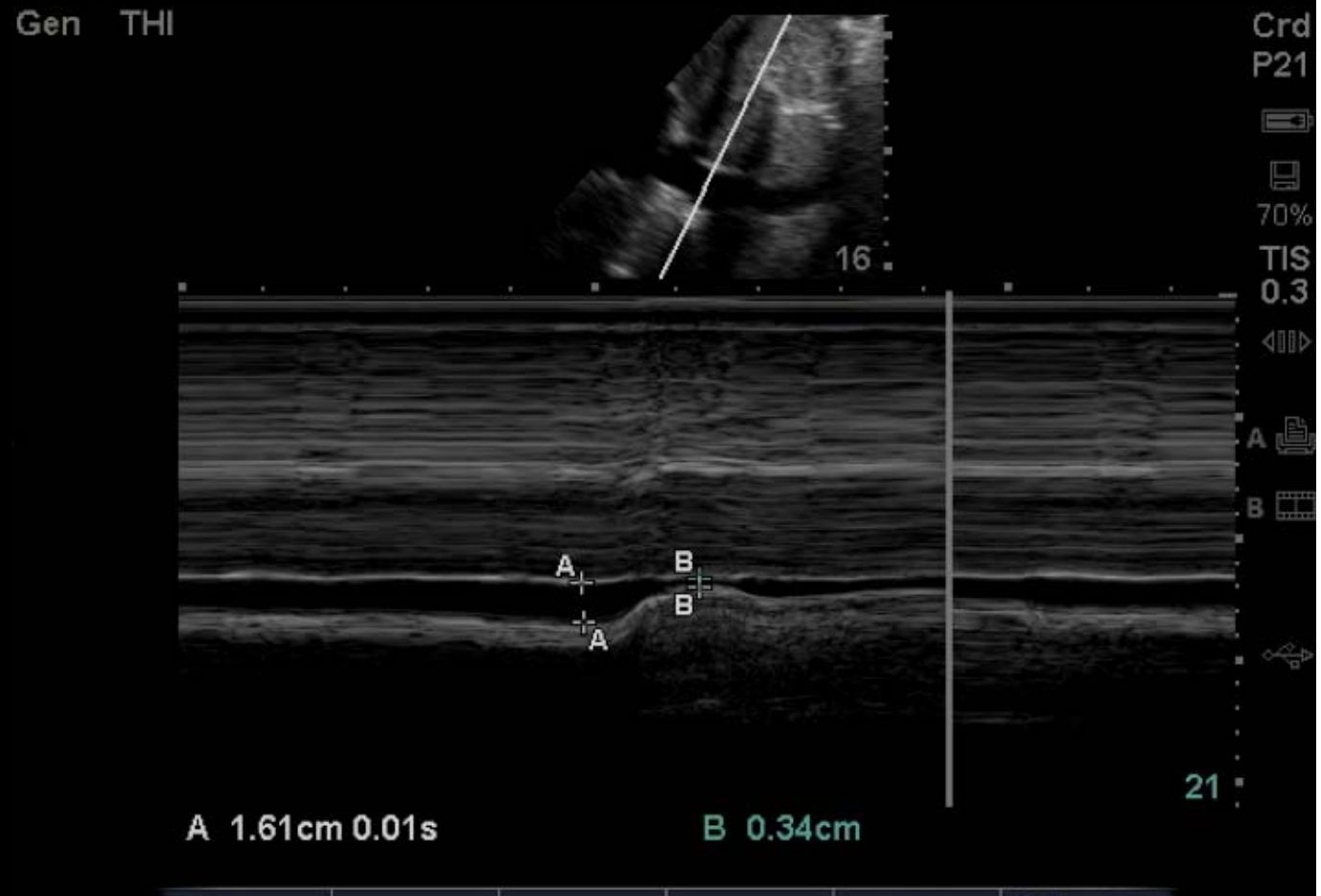
- a) Panic attack
- b) Asthma attack
- c) Massive PE
- d) All of the above



7.8

5. Based on this IVC M-mode image, this shocked patient is most likely:

- a) 'Empty'
- b) Euvolaemic
- c) 'Full'



## 6. IVC M-mode image. This is consistent with:

- a) Congestive cardiac failure
- b) Pericardial tamponade
- c) Pulmonary embolus
- d) Chronic cor pulmonale
- e) All of the above

