IVC
‘The pro-BNP of ultrasound’

Dr Justin Bowra
Critical Care Ultrasound Course

IVC SUMMARY

- Subxiphoid probably best window
- Combine long axis and transverse view
- Hepatic vein confluence
- Maximum diameter (IVCD)
- Change with inspiration (IVCCI: IVC collapsibility index)
- Only really useful at extremes
- Fat/ round … or flat & skinny?

The inferior vena cava (IVC)

- Largest vein in the body
- To the anatomical right of aorta
- Oval, thin walled
- Breathe in: diameter ↓ (opposite if ventilated)
- Dehydration: ‘flattens out’.
- Downstream occlusion (eg tamponade) or fluid overload (eg CCF): ‘fattens up’.

Subxiphoid longitudinal: shocked & dry

Subxiphoid transverse: massive PE

The IVC can help us in the resus room.

Diagnosis: Is there fluid overload or a downstream occlusion (eg PE, tamponade)?

Resuscitation: Should I give more IV fluids to this shocked patient?

Parameters

Shape (fat or flat?)

Maximum IVC diameter (IVCD)

IVC collapsibility index (IVCCI) = (max – min)/max x100

IVCCI (hypovolaemia) = 69%

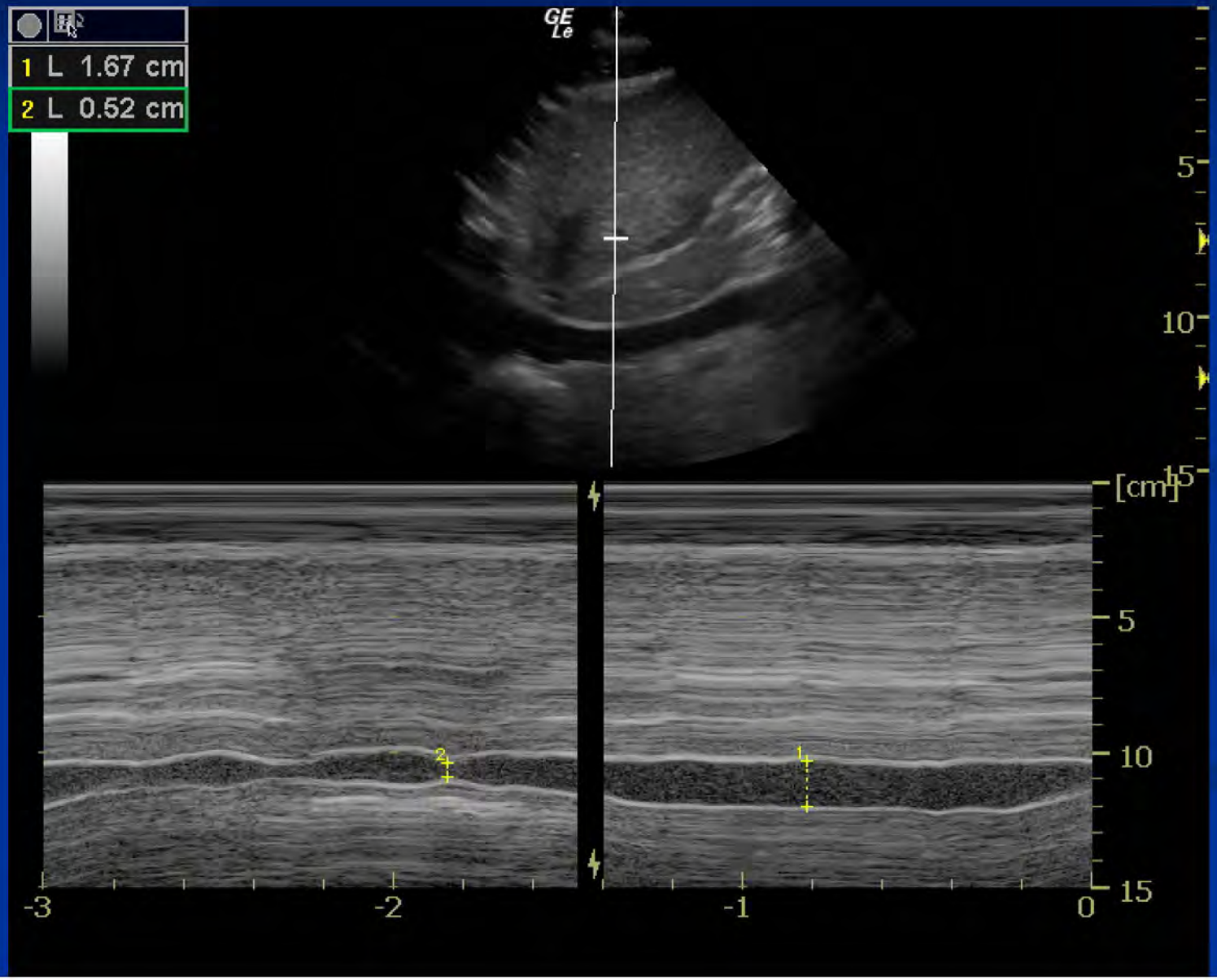

IVCCI (CCF) = 10%

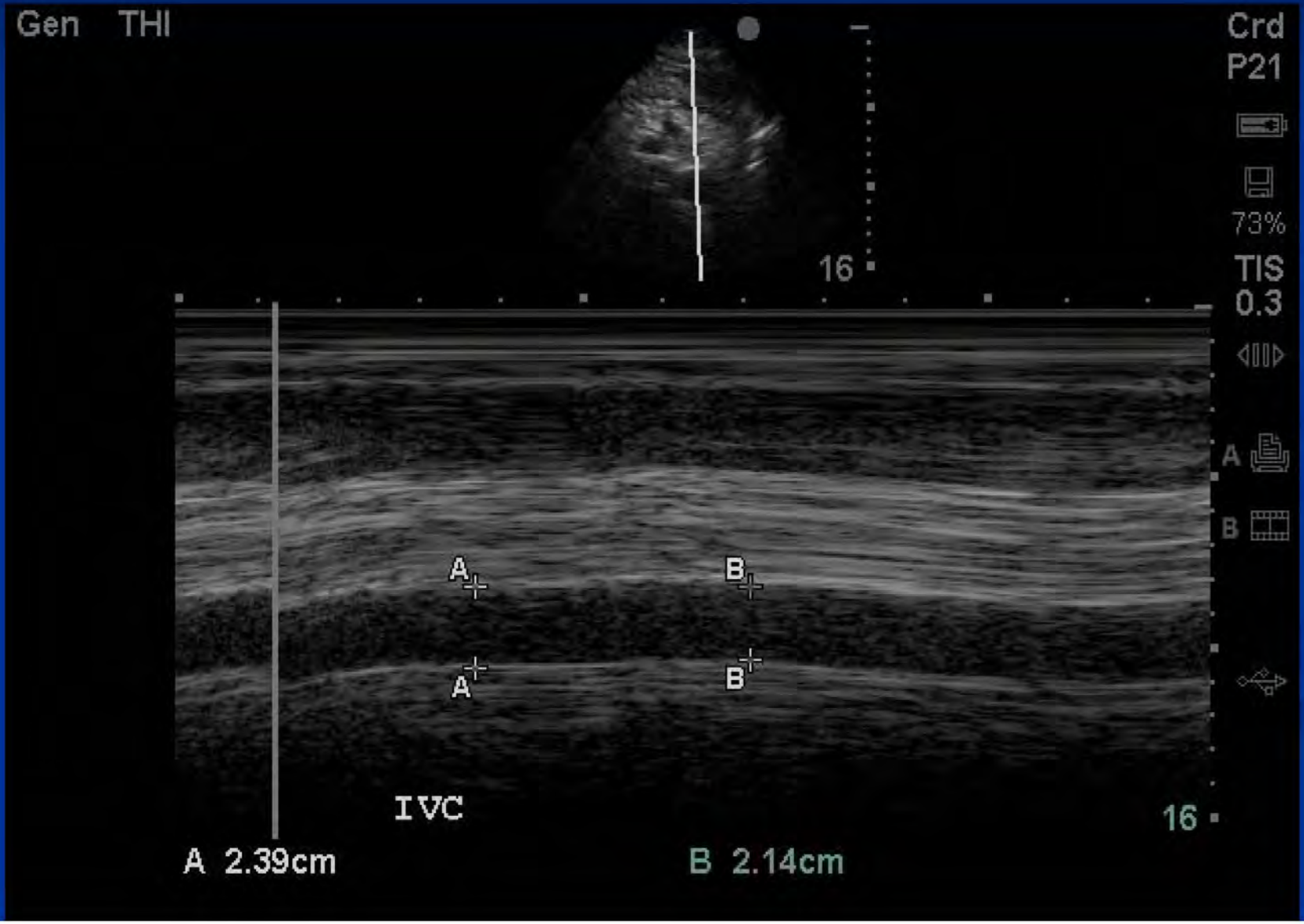

IVC: the good news

Cheap

Easy to find & measure

Noninvasive

Rapid

Repeatable

IVC: the bad news

Poorly validated

Only useful at extremes

No-one really knows where / how to measure it

How to image the IVC

What probe?
What preset?
Where?
How?

What probe should we use?

Curved or sector

What preset?

Abdo (FAST) or cardiac

Where should we put the probe?

How should we align it?

Where should we put the probe?

How should we align it?

NO-ONE KNOWS!

Subxiphoid long axis

Subxiphoid long axis

- Most studies & experts measure here
- Probe sagittal
- Angled up through the liver
- Find the right atrium: confirm IVC entering RA
- Find the hepatic veins entering IVC
- ‘Hepatic vein confluence’

Subxiphoid long axis

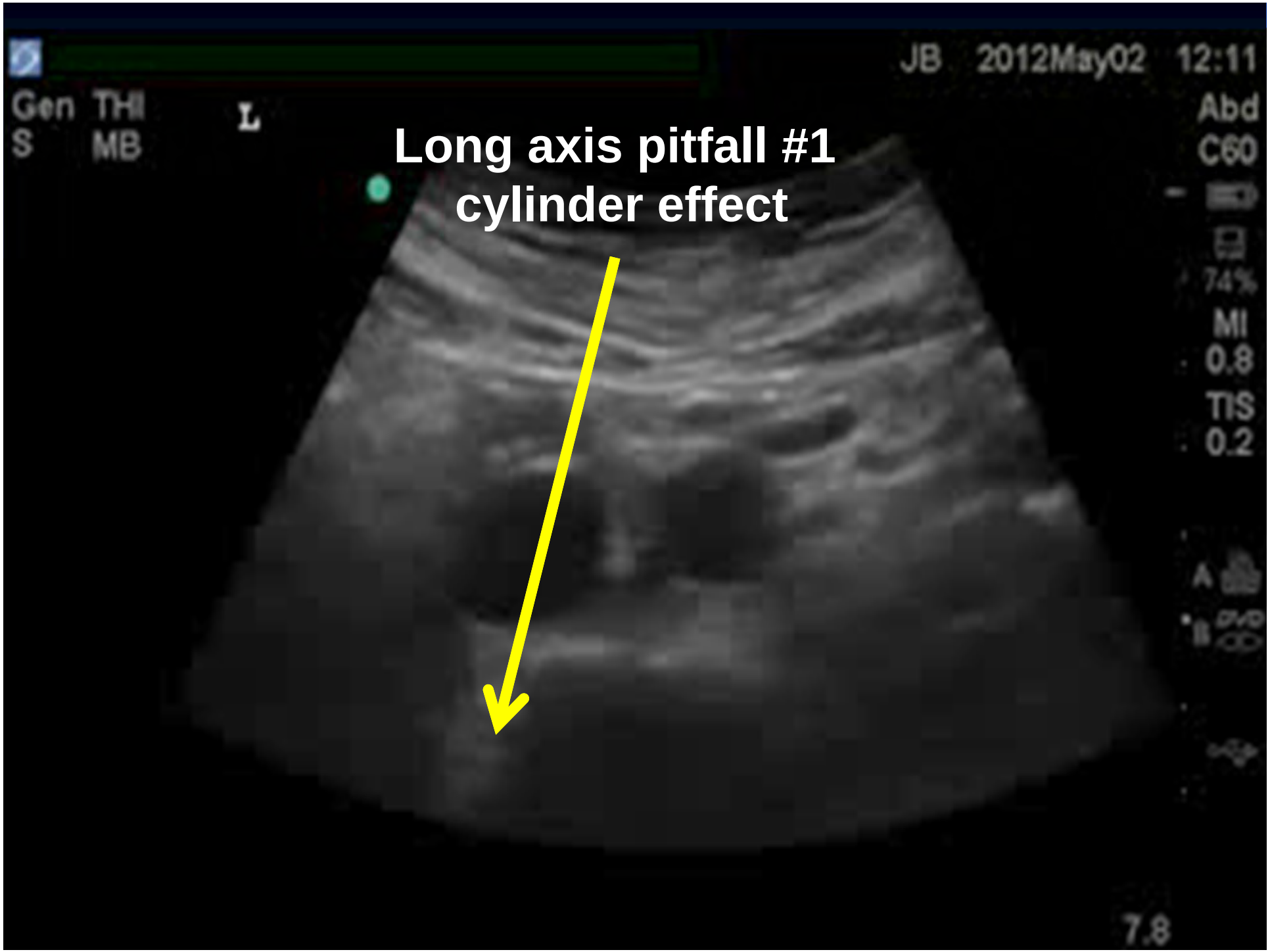
Long axis pitfall #1
cylinder effect
JB 2012May02 12:11
Gen THI
S MB
L
Abd
C60
74%
MI
0.8
TIS
0.2
7.8

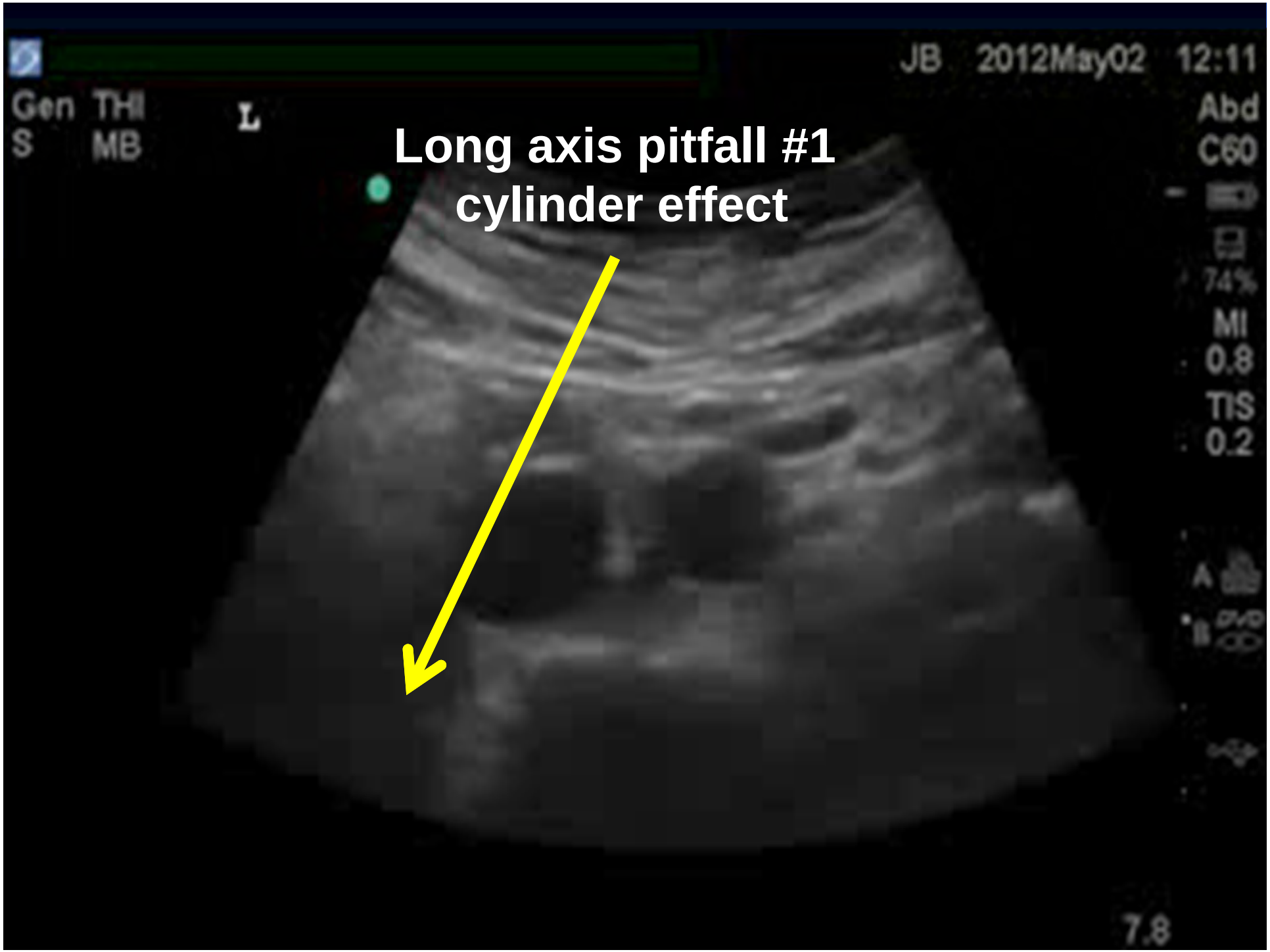
Long axis pitfall #1
cylinder effect
JB 2012May02 12:11
Gen THI
S MB
L
Abd
C60
74%
MI
0.8
TIS
0.2
7.8

Long axis pitfall #2
IVC lateral movement



Subxiphoid short axis

Subxiphoid short axis

- RUSH protocol (& a small study by Akilli) recommend this one
- Probe in same spot as before
- But turned to transverse
- IVC imaged in short axis

Subxiphoid short axis

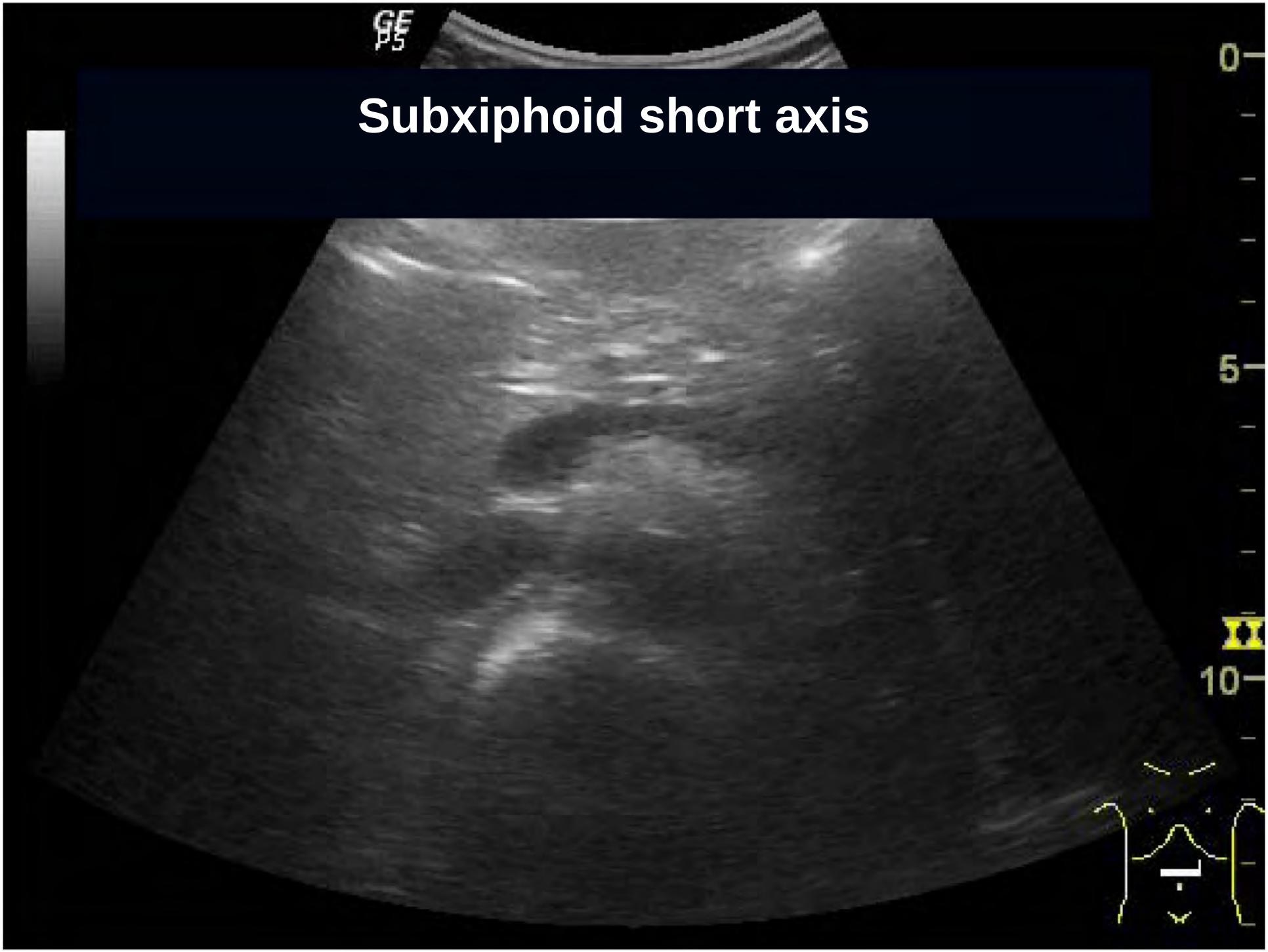

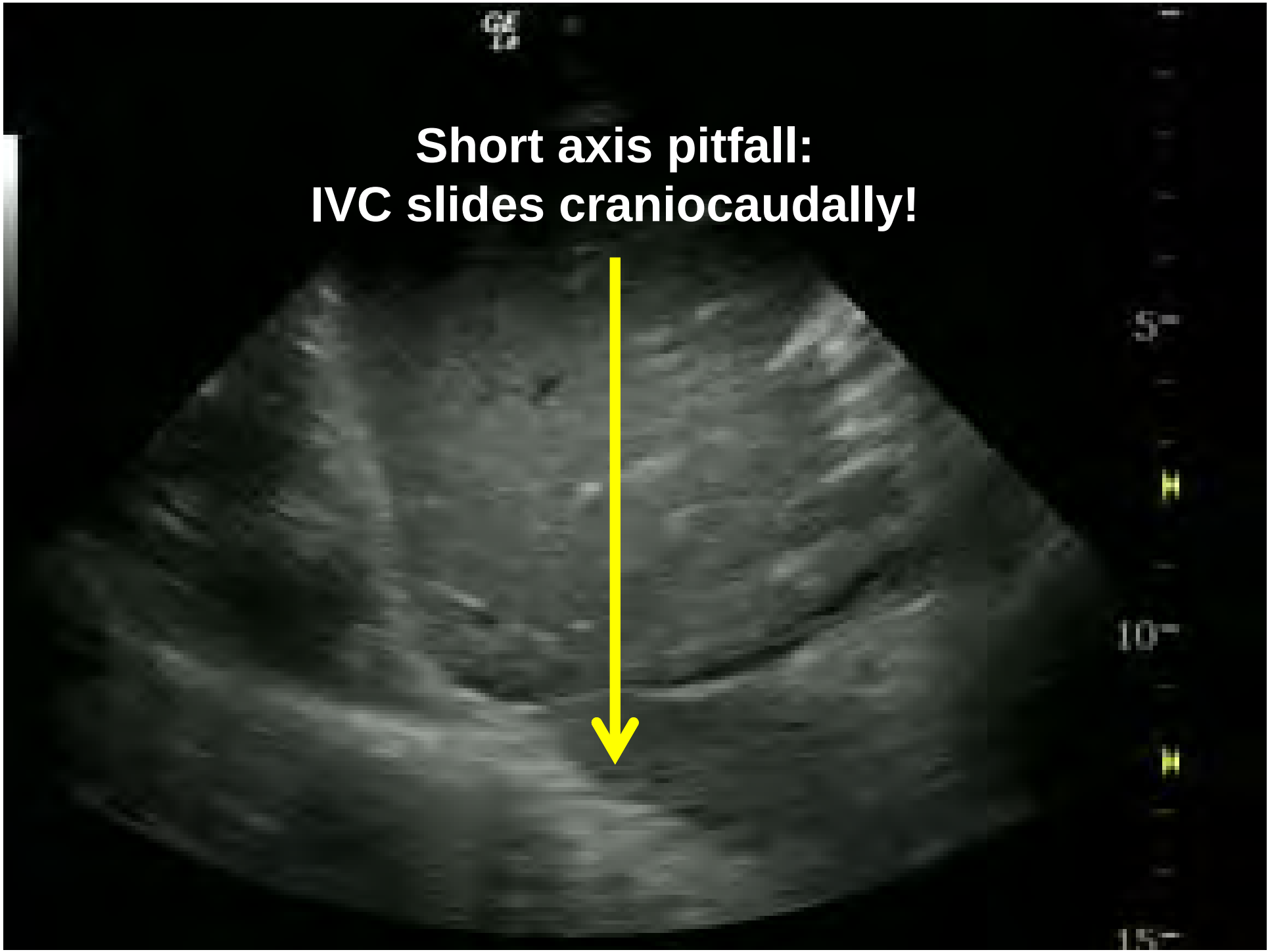
Short axis pitfall:
IVC slides craniocaudally!

Midaxillary long axis: ACEP website recommends as an alternative.

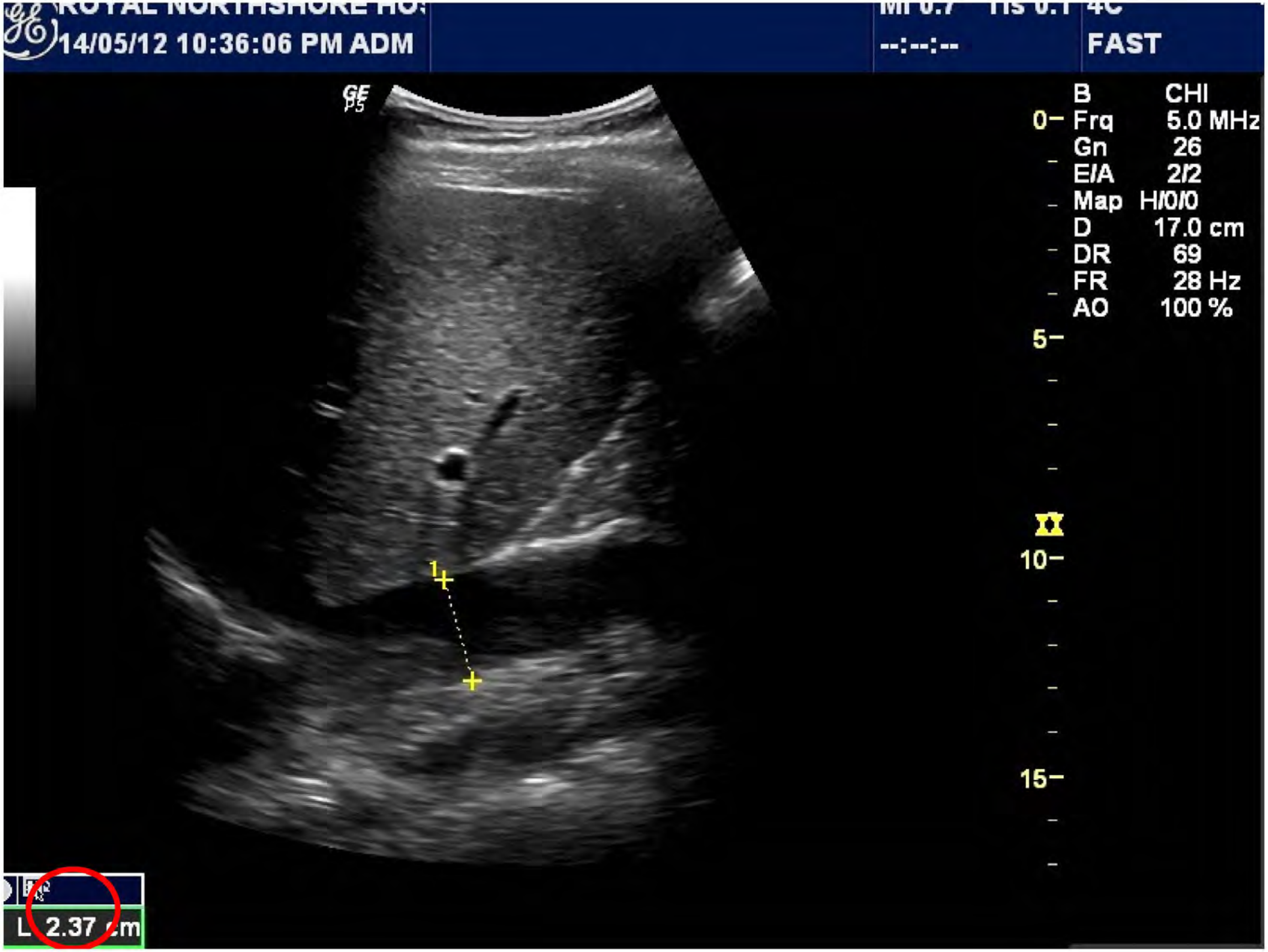
14/05/12 10:36:06 PM ADM
--:--:--
FAST
GE
P5
B CHI
Frq 5.0 MHz
Gn 26
E/A 2/2
Map H/0/0
D 17.0 cm
DR 69
FR 28 Hz
AO 100 %
0
5
10
15
1
L 2.37 cm

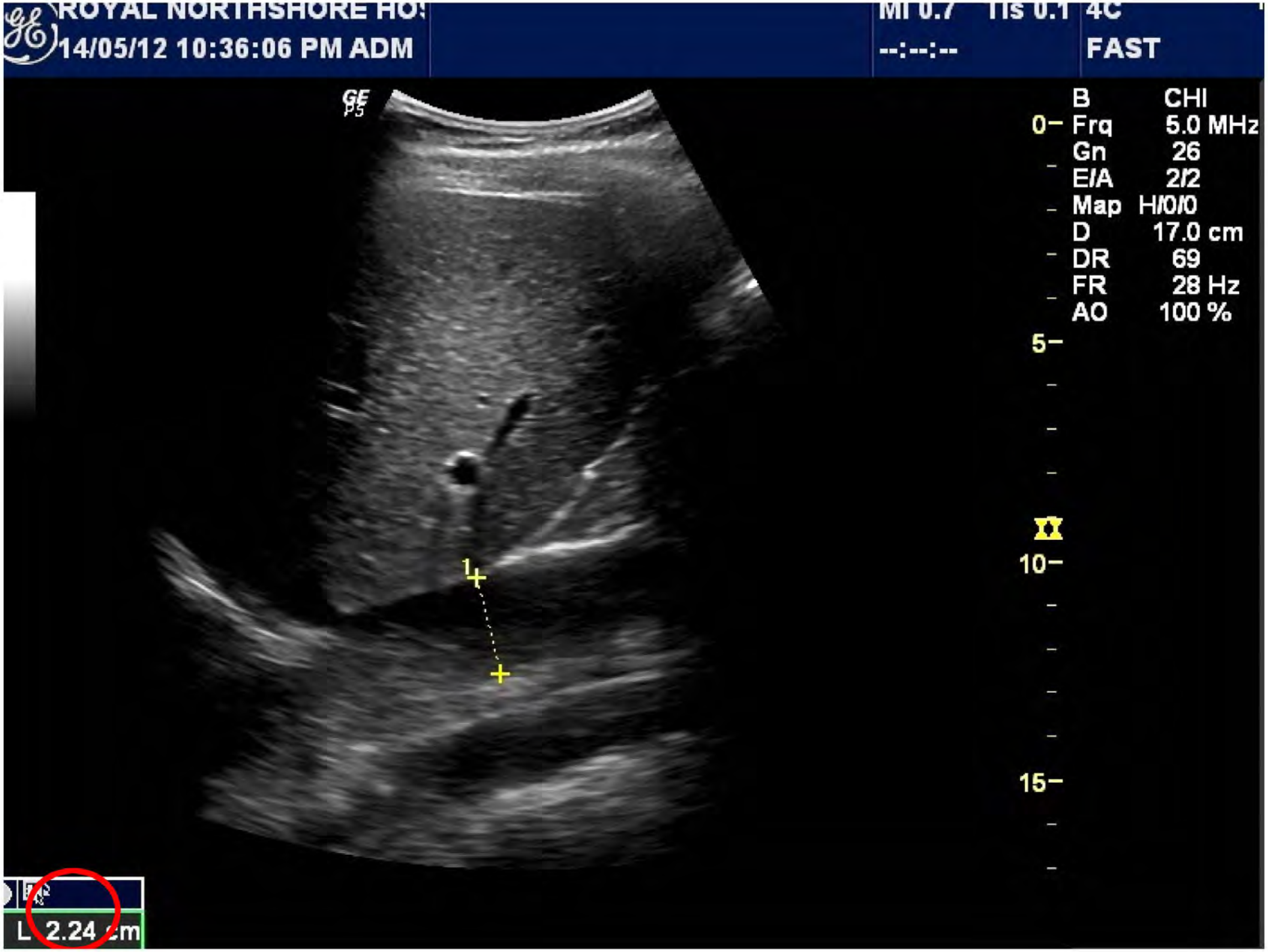
ROYAL NORTHSHORE HO
14/05/12 10:36:06 PM ADM
MI 0.7
TIs 0.1
4C
--:--:--
FAST
B CHI
Frq 5.0 MHz
Gn 26
E/A 2/2
Map H/0/0
D 17.0 cm
DR 69
FR 28 Hz
AO 100 %
0
5
10
15
1
L 2.24 cm

Subxiphoid trans: MAX & MIN.

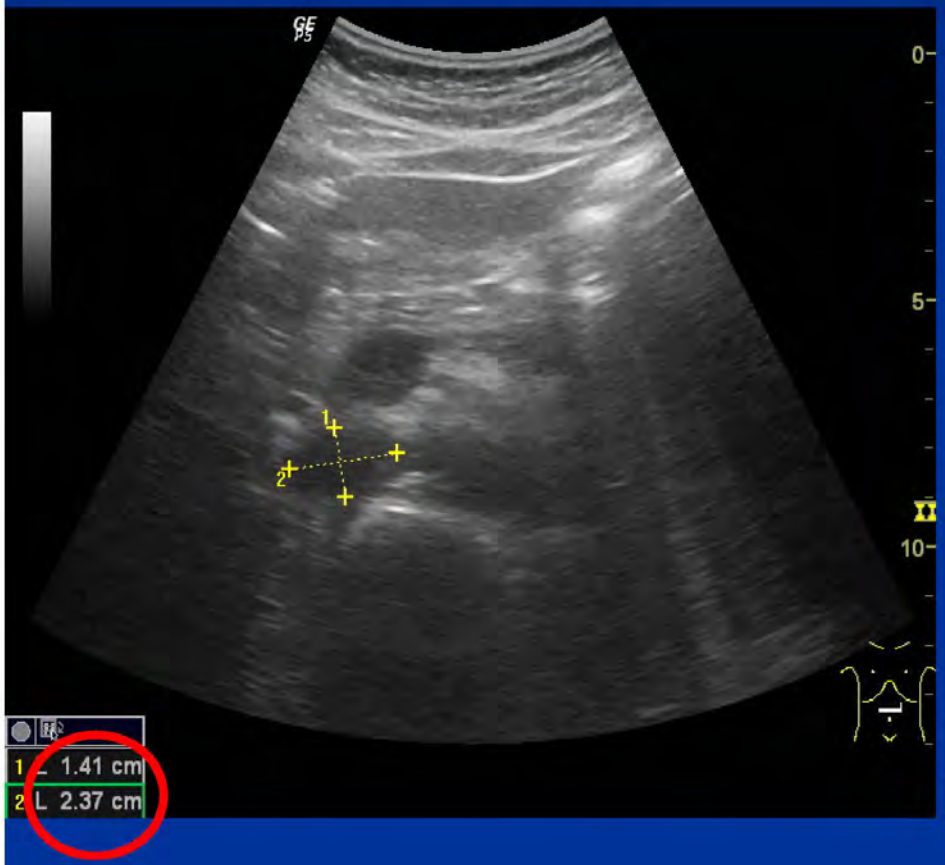

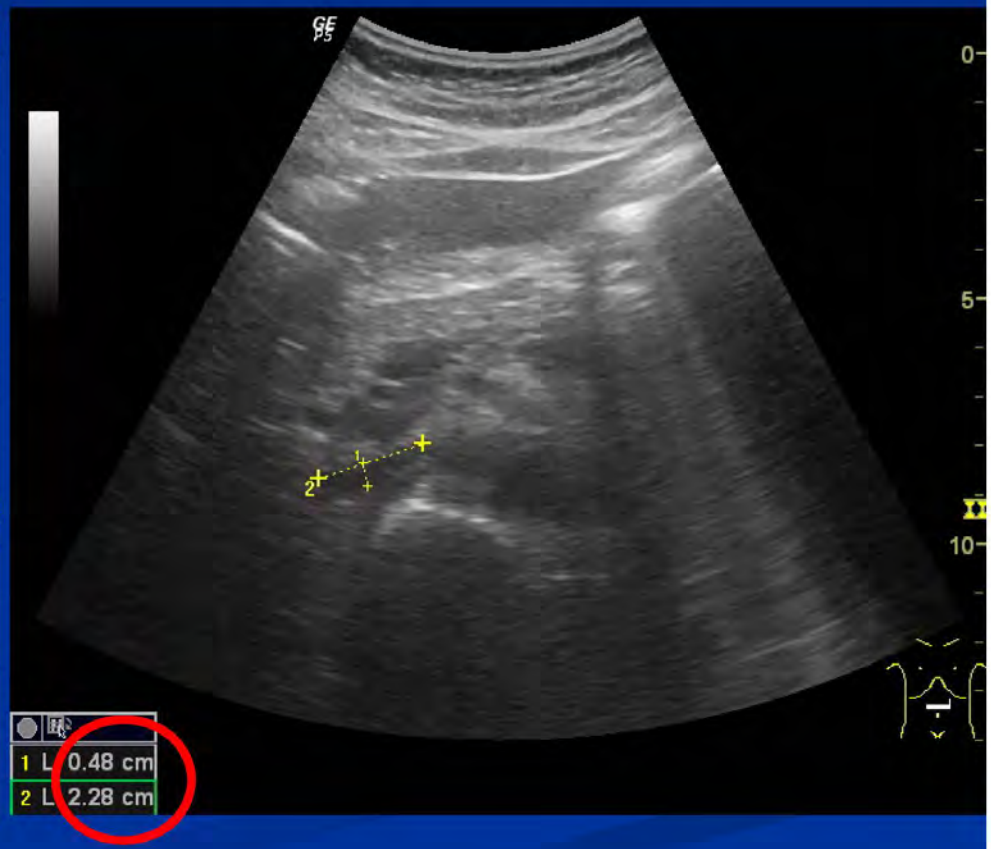

Watch how the IVC collapses (subxiphoid)

Watch how the IVC collapses (RUQ)

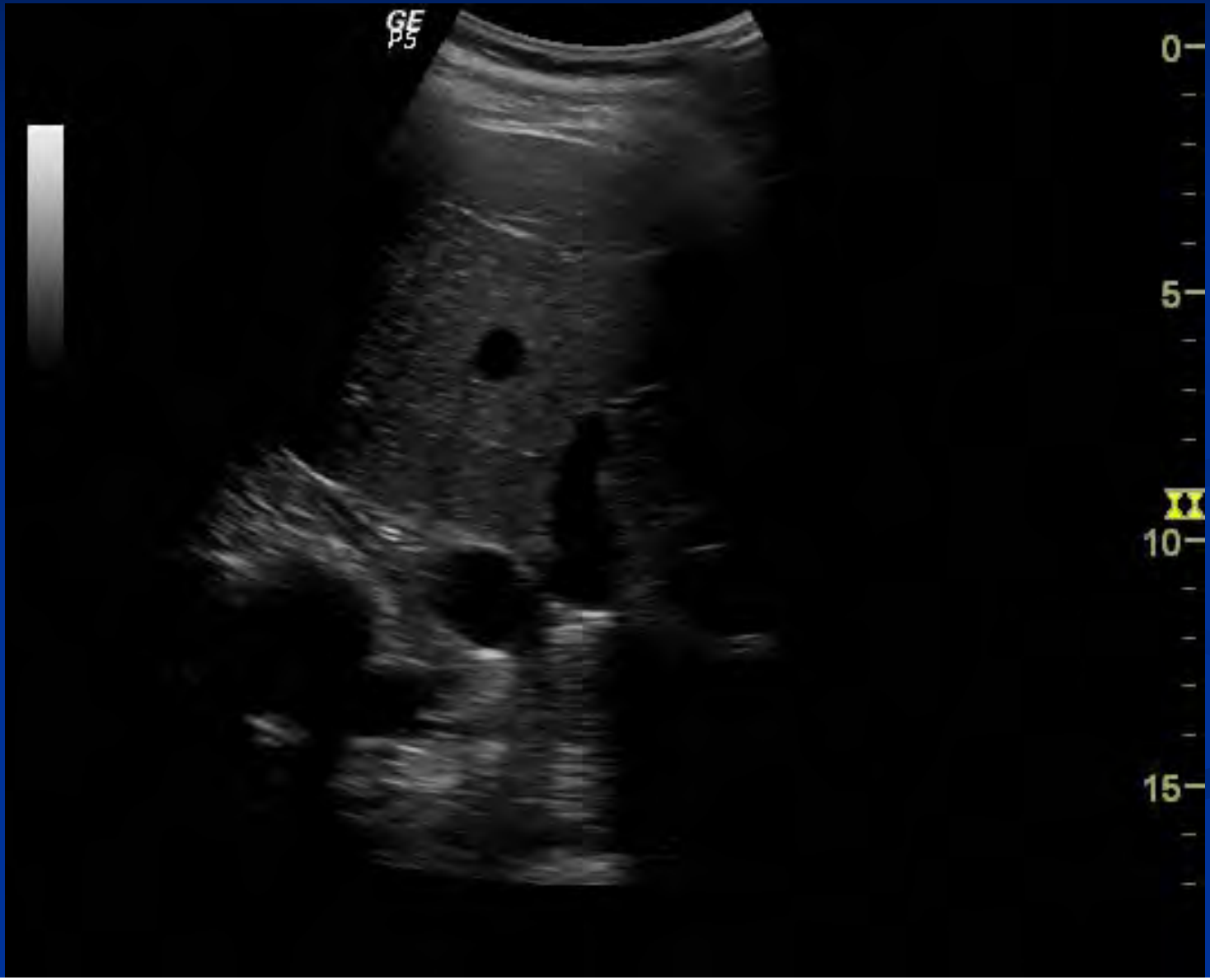

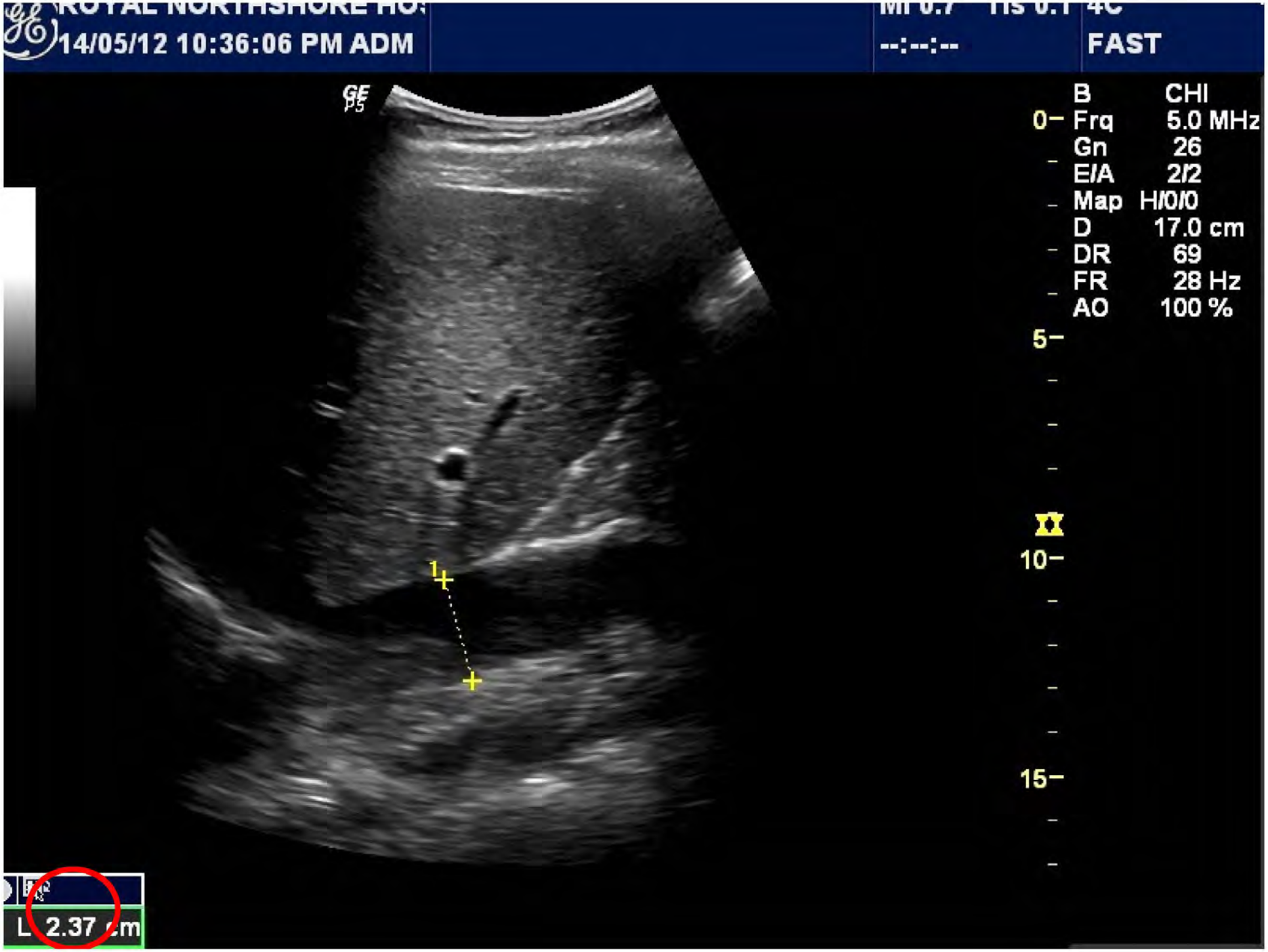
14/05/12 10:36:06 PM ADM
--:--:--
FAST
GE
P5
B CHI
Frq 5.0 MHz
Gn 26
E/A 2/2
Map H/0/0
D 17.0 cm
DR 69
FR 28 Hz
AO 100 %
0
5
10
15
1
L 2.37 cm

Subxiphoid long axis approach: probably OK (if you're careful).

Midaxillary longitudinal approach: probably not OK.

Any transverse view: dunno.

Transpyloric window: dunno.

No-one's really sure.

Where should we measure the IVC?

Where should we put the calipers?

No-one knows!

The IVC collapses non-uniformly

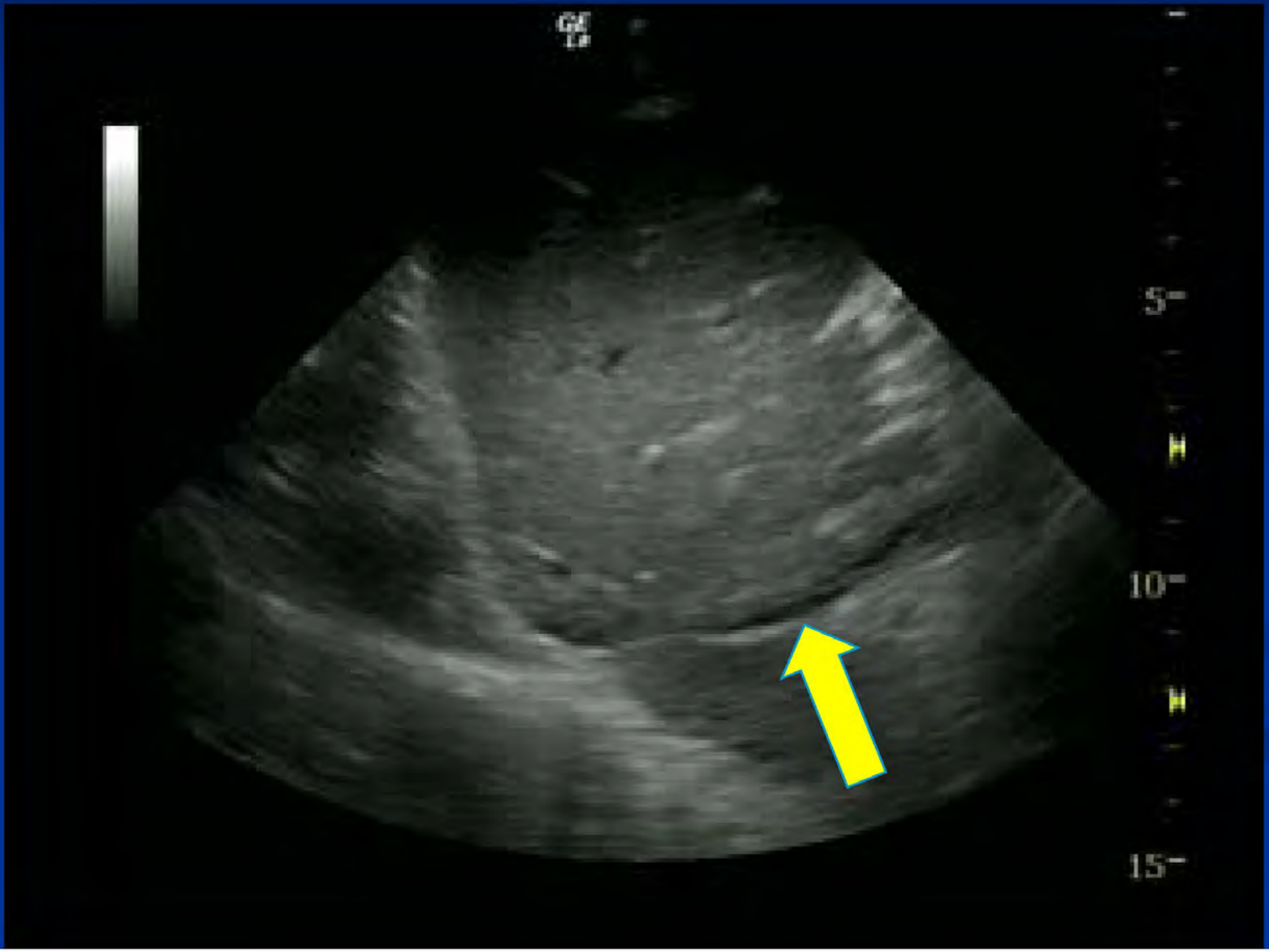

The IVC collapses non-uniformly

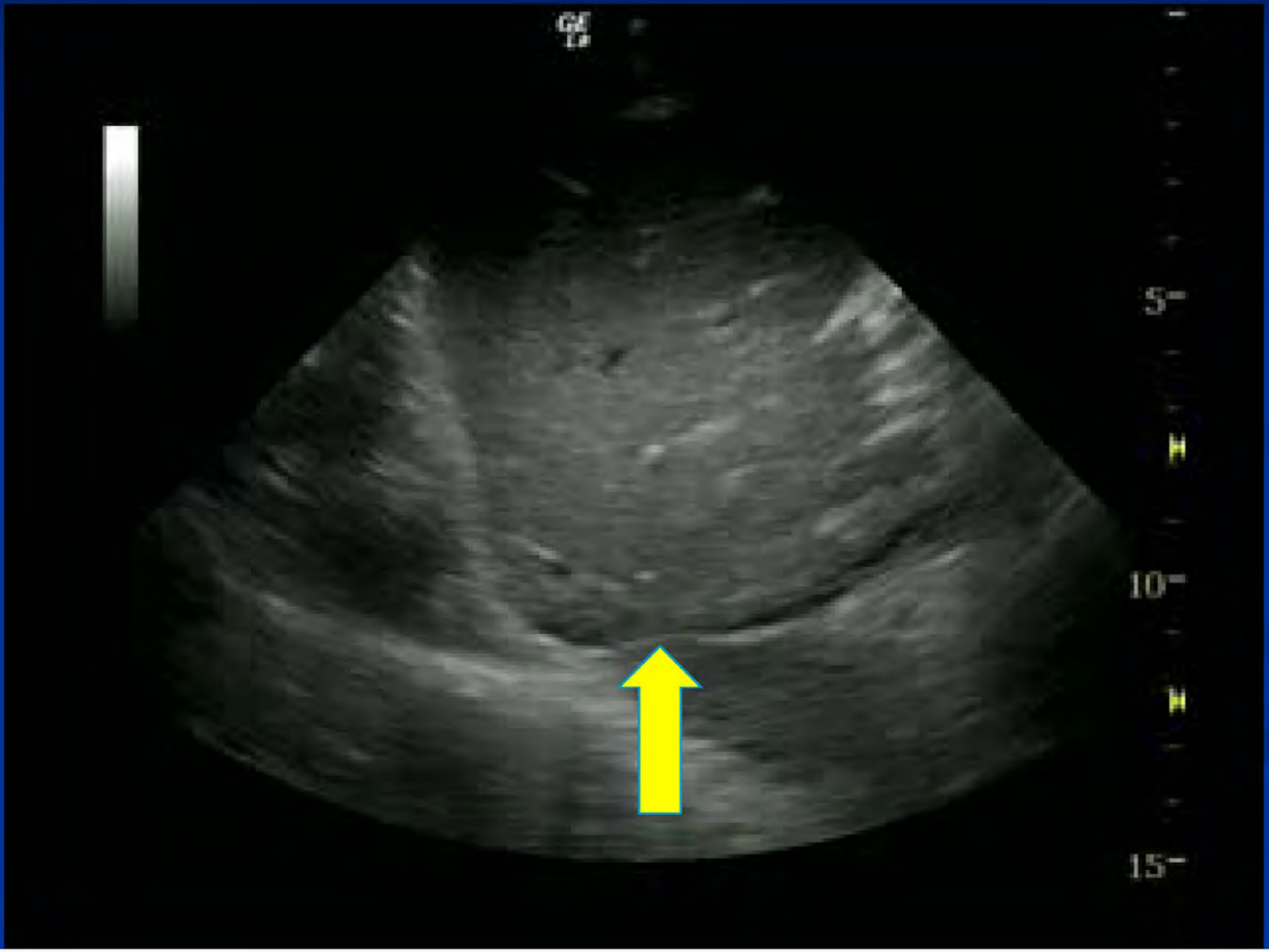

Most of us measure at/near the confluence with the hepatic veins.

This is where most of the numbers / guidelines come from.

Below the liver (eg transpyloric) might be OK, but is probably more prone to probe pressure.

Should I use M-mode?

M-mode pitfalls:
wrong angle, and IVC moves

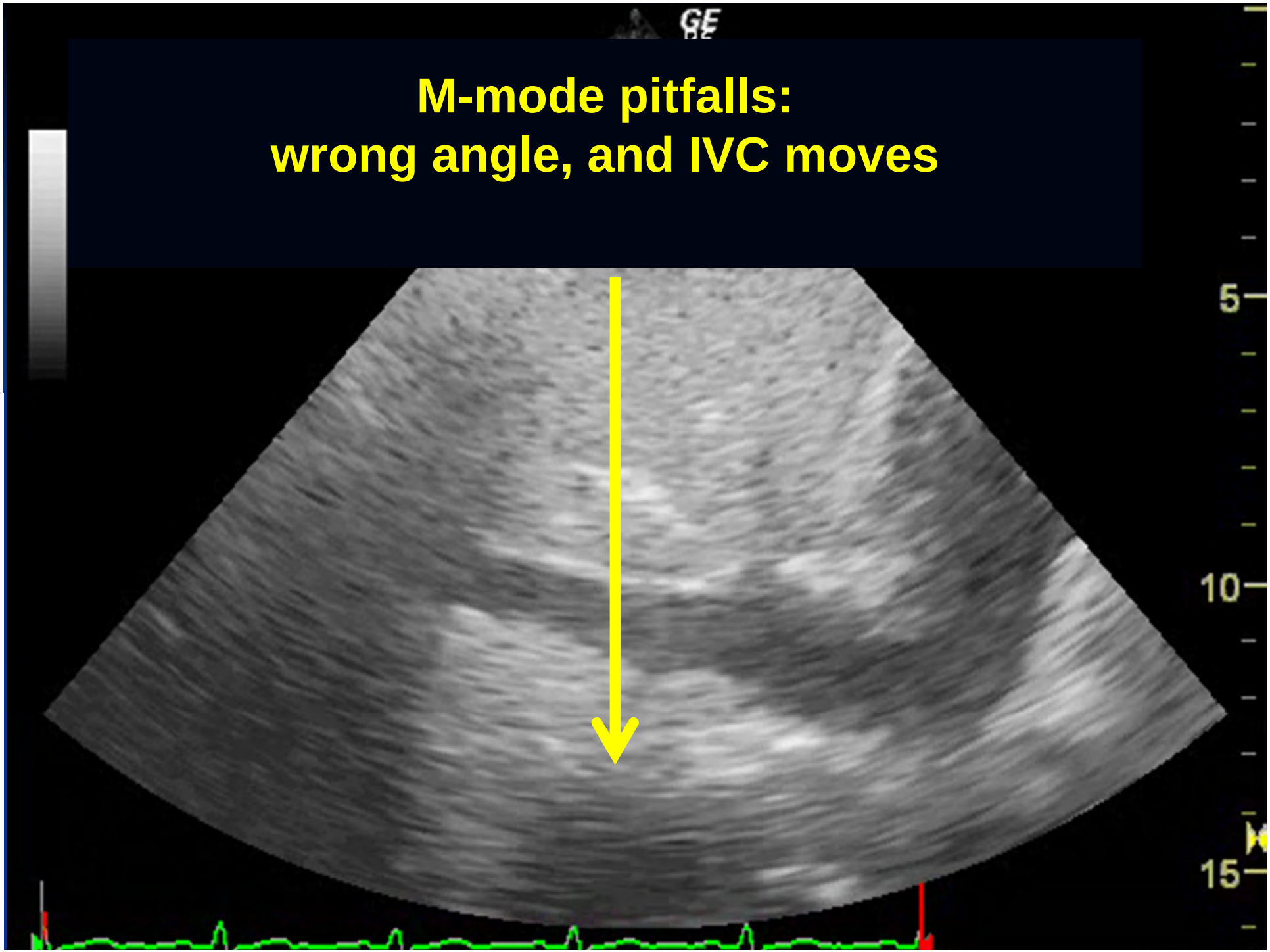

Top tip:

When starting out, avoid M-mode.

Should I do a sniff test?

Sniff test (great in healthy volunteers)

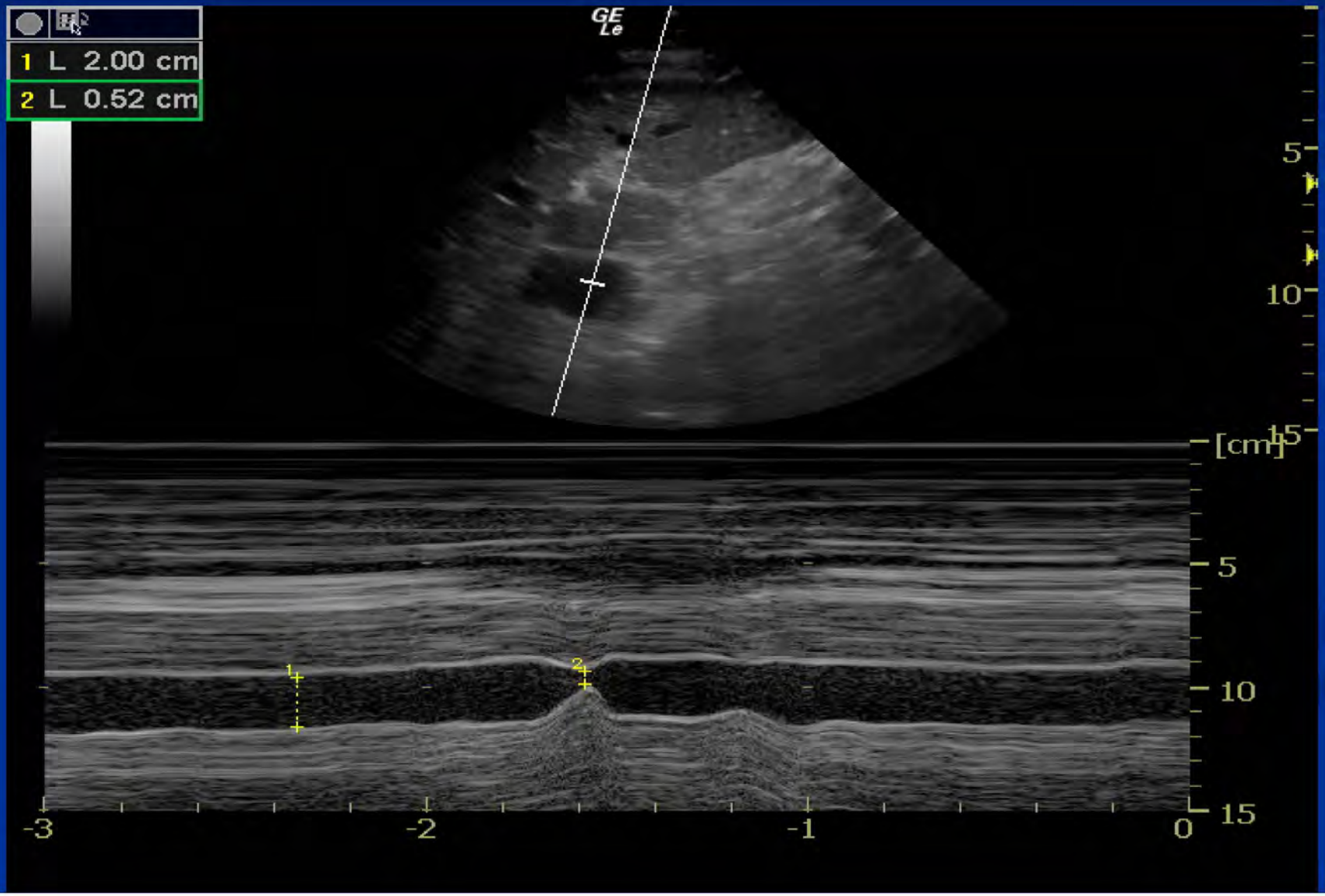

If the patient is well enough to perform a sniff test, you probably don’t need to be looking at their IVC.


predicting
Fluid
responsiveness

ASE guidelines 2005

IVC diameter (cm)	IVCCI	Estimated RA pressure (mm Hg)
<1.7	>50%	0-5
>1.7	>50%	6-10
>1.7	<50%	11-15
‘dilated’	none	>15

Not validated in critically ill patients.

Based on sonographer measurements (which don't correlate with clinician measurements).

Validated against CVP, not against anything useful.

ASE guidelines 2005

IVC diame (c	IVCCI	Estimated essure lg)
<		
>1.7		6-10
	%	
‘dilated’	none	>15

So what can the IVC really tell us?

In shocked patients:

	IVCD	IVCCI	Correlation
Spontaneously breathing	<0.9cm	>50%	*Probably* empty / fluid responsive
	?	<15%	*Probably* full & unresponsive
	Anything else		Dunno
Ventilated	<1.2cm	>18%	*Probably* empty/ responsive
	>2.5cm	<10%	*Probably* full/ unresponsive
		Or PE/ PTX/ tamponade Or other stuff that raises CVP	

Why is this so?

1. IVC just isn’t that precise.

2. CVP isn’t great as a marker of fluid status.

IVC ultrasound: summary

1: How to image the IVC

- Subxiphoid long axis (or midaxillary trans)
- Curved or sector probe
- Abdo (FAST) preset if possible
- Don’t use M mode
- Don’t do a sniff test
- Eyeball assessment is probably fine

2: How to assess the IVC

- Practise with calipers (IVCD, IVCCI)
- But once you get your ‘eye in’, eyeball assessment is fine
- Stick to extremes:
- Flat & collapsing = probably empty
- Full & not collapsing = probably full!!

3: Beware the 'mimics'

Flat & collapsing IVC

- Probe pressure
- Raised intra-abdo pressure
- Manner of breathing

Full & not collapsing

- Tension PTX
- Tamponade
- Massive PE
- Severe COPD, Status asthmaticus?
- Any right heart disease

4. Be a doctor

- Clinical assessment is always the best
- Add lung US (wet or dry? PTX? Chunky?)
- Add basic echo (Tamponade? Massive RV?)
- And the rest: CXR, ECG, etc etc
- If US findings don't match clinical assesment, turn off the machine

Thanks to

Dr Kylie Baker (for that literature review)

Dr Adrian Goudie (for that IVC long axis image)

Drs Mike Blaivas, Matt Dawson, Mike Mallin, Cliff Reid & Scott Weingart (for their advice & input)

References

- ACEP http://www.acep.org/Content.aspx?id=80791
- Akilli B, Bayir A et al. Inferior vena cava diameter as a marker of early hemorrhagic shock: a comparative study. Ulus Travma Acil Cerrahi Derg 2010;16(2):113-8.
- Baker, K. Review of Bedside Sonography for Guidance of Fluid Therapy in the Emergency Department. (unpublished)
- Barbier C, Loubières Y, Schmit C, Hayon J, Ricôme JL, Jardin F, Vieillard-Baron A. Respiratory changes in inferior vena cava diameter are helpful in predicting fluid respon- siveness in ventilated septic patients. Intensive Care Med 2004; 30:1740–1746
- Blehar DJ, Dickman E, Gaspari R. Identification of congestive heart failure via respiratory variation of inferior vena cava. Am J Em Med 2009;27:71–5.
- Blehar et al. Inferior vena cava displacement during respirophasic ultrasound imaging. Critical Ultrasound Journal 2012, 4:18

References

- Charron C, Caille V, Jardin F, Viellard-Baron A. Echocardiographic measurement of fluid responsiveness. *Curr Op Crit Care* 2006; 12(3): 249-54.
- Corl K, Napoli A, Gardiner F. Bedside sonographic measurement of the inferior vena cava caval index is a poor predictor of fluid responsiveness in emergency department patients. Emergency Medicine Australasia (2012) 24, 534–539
- Dipti A et al. Role of inferior vena cava diameter in assessment of volume status: a meta-analysis. AJEM 2012 (30). 1414 -19.
- Feissel M, Michard F, Faller JP, Teboul JL (2004) The respiratory variation in inferior vena cava diameter as a guide to fluid therapy. Intensive Care Med 30:1834–1837
- Jue J, Chung W, Schiller NB. Does inferior vena cava size predict right atrial pressures in patients receiving mechanical ventilation. J Am Soc Echocardiogr 1992; 5: 613-9.

References

- Kimura BJ, Dalugdugan R, Gilcrease GW 3rd, Phan JN, Showalter BK, Wolfson T. The effect of breathing manner on inferior vena caval diameter. Eur J Echocardiogr. 2011 Feb;12(2):120-3
- Kircher B, Himelman R, Schiller N. Noninvasive estimation of right atrial pressure from the inspiratory collapse of the inferior vena cava. *AM J Cardiol* 1990; 66: 493-6.
- Lang RM, Bierig M, Devereux F *et al* Recommendations for chamber quantification: a report from the American Society of Echocardiography's guidelines and standards committee and the chamber quantification writing group, developed in conjunction with the European Association of Echocardiography, ad branch of the European Society of Cardiology. *J Am Soc Echocardiogr* 2005; **18**: 1440-63.
- Lanspa MJ, Grissom CK et al. Applying dynamic parameters to predict hemodynamic response to volume expansion in spontaneously breathing patients with septic shock. Shock 2013. 39(2). pp. 155-160

References

- Medscape http://www.medscape.com/viewarticle/727097
- Moretti R, Pizzi B. Inferior vena cava distensibility as a predictor of fluid responsiveness in patients with subarachnoid hemorrhage. Neurocrit Care. 2010 Aug;13(1):3-9.
- Muller L et al. Respiratory variations of inferior vena cava diameter to predict fluid responsiveness in spontaneously breathing patients with acute circulatory failure: need for a cautious use. Critical Care 2012, 16:R188
- Nagdev AD, Merchant RC, Tirado-Gonzalez A, Sisson CA, Murphy MC. Emergency Department Bedside Ultrasonographic Measurement of the Caval Index for Noninvasive Determination of Low Central Venous Pressure. Ann Emerg Med. 2010 Mar;55(3):290-5
- Perera P et al. The RUSH Exam 2012: Rapid Ultrasound in Shock in the Evaluation of the Critically Ill Patient. Em Med Clinics. Ultrasound Clin 7 (2012) 255–278

References

- Randazzo MR, Snoey ER, Levitt MA, et al. Accuracy of emergency physician assessment of left ventricular ejection fraction and central venous pressure using echocardiography. Acad Emerg Med 2003;10:973–7.
- Sefidbakht S, Assadsangabi R, Abbasi HR, Nabavizadeh A. Sonographic measurement of the inferior vena cava as a predictor of shock in trauma patients. *Emerg Radiol* 2007; **14(3)**: 181-185.
- Stanford University. http://www.stanford.edu/group/ccm_echocardio/cgi-bin/mediawiki/index.php/IVC
- Takata M, Wise RA, Robotham JL. Effect of abdominal pressure on venous return: abdominal vascular zone conditions. J Appl Physiol 1990 (69):1961– 1972
- **ultrasoundpodcast http://www.ultrasoundpodcast.com/?s=ivc)**

References

- Wallace DJ, Allison M, Stone MB. Inferior vena cava percentage collapse during resuscitation is affected by the sampling location: an ultrasound study in healthy volunteers. Acad Emerg Med 2010;17:96–9.
- Weekes A, Tassone HM, Tayal VS, Babcok AJ, Norton J. Sonodynamic Comparison of Systolic Blood Pressure to Aortic Velocity Time Integral Measurements as a Measure of Fluid Responsiveness In Non-Traumatic Symptomatic Hypotensive Emergency Department Patients. Annals of Emergency Medicine 2010. Volume 56, Issue 3 Suppl, pS76
- Weekes AJ, Tassone HM, Babcock A, et al. Comparison of serial qualitative and quantitative assessments of caval index and left ventricular systolic function during early fluid resuscitation of hypotensive emergency department patients. Acad Emerg Med 2011; 18(9):912-21.

References

- Yanagawa Y, Nishi K, Sakamoto T, Okada Y. Early diagnosis of hypovolemic shock by sonographic measurement of inferior vena cava in trauma patients. *J Trauma* 2005; **58(4)**: 825-829.
- Yanagawa Y, Sakamoto T, Okada Y. Hypovolemic shock evaluated by sonographic measurement of the inferior vena cava during resuscitation in trauma patients. *J Trauma* 2007; **63(6)**: 1245-1248.