

Case

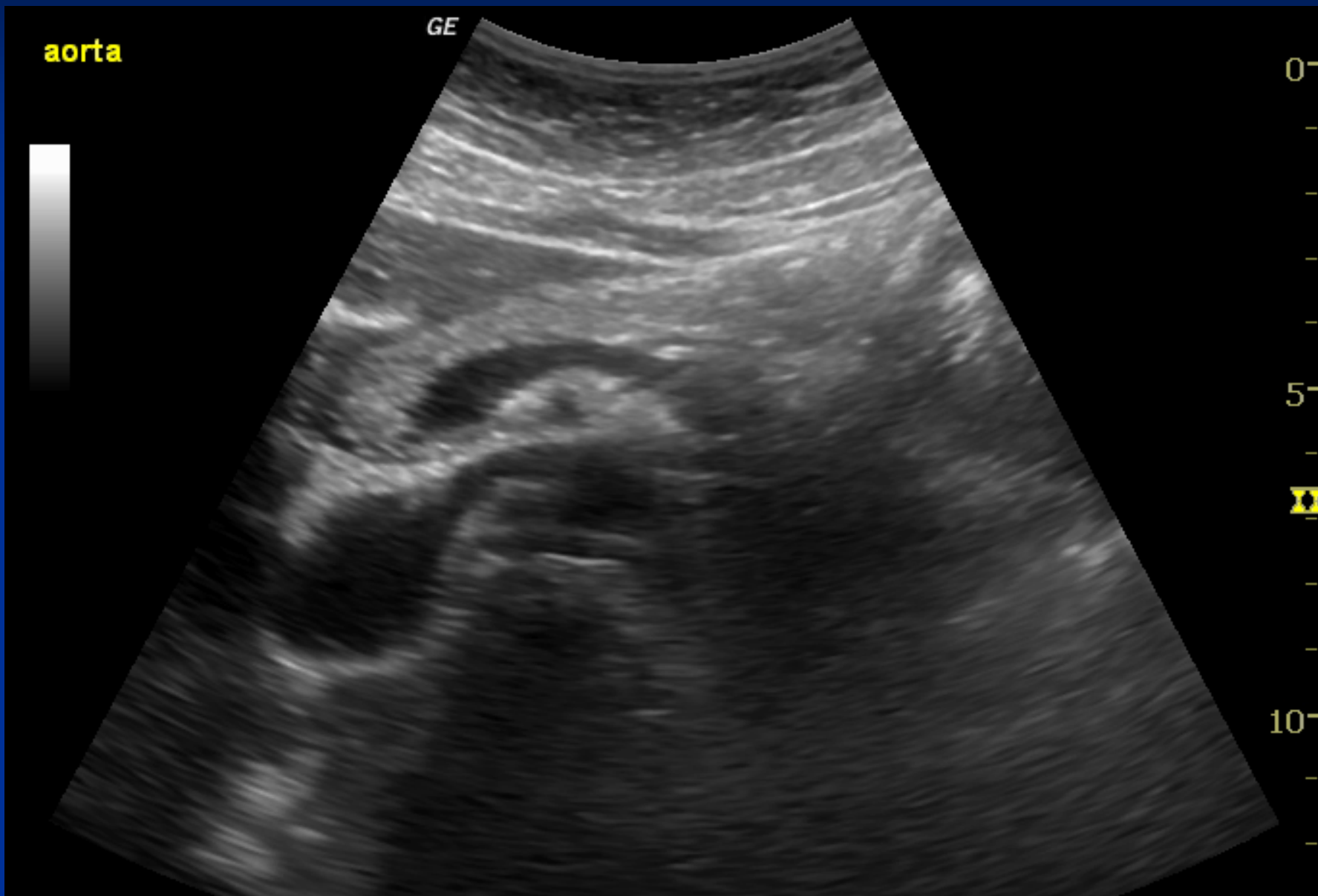
Abdo pain

Emergency Ultrasound Course
Justin Bowra

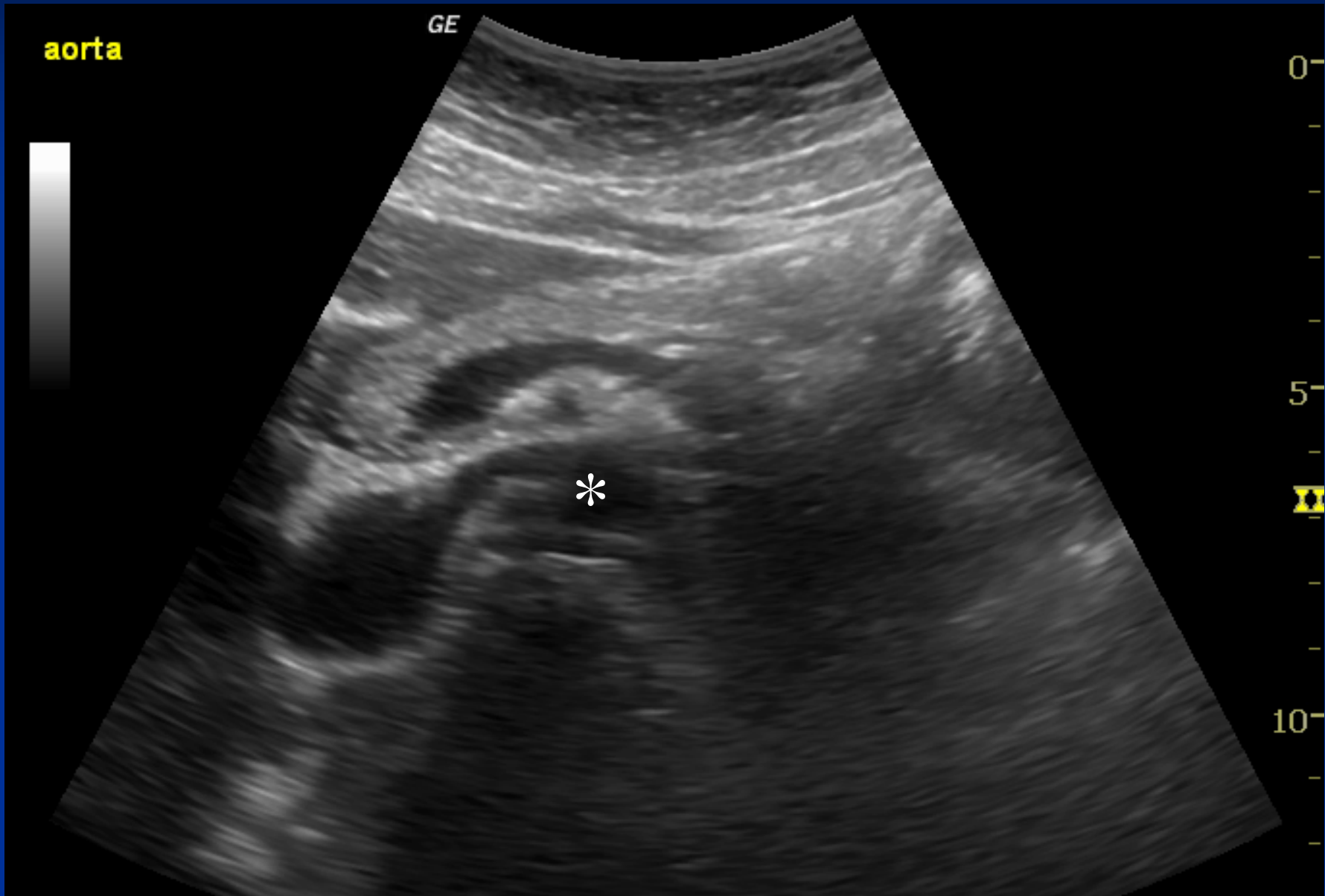
Clinical scenario

- 75 year old male
- Sudden onset epigastric pain
- Shocked, diaphoretic, ashen
- AAA?

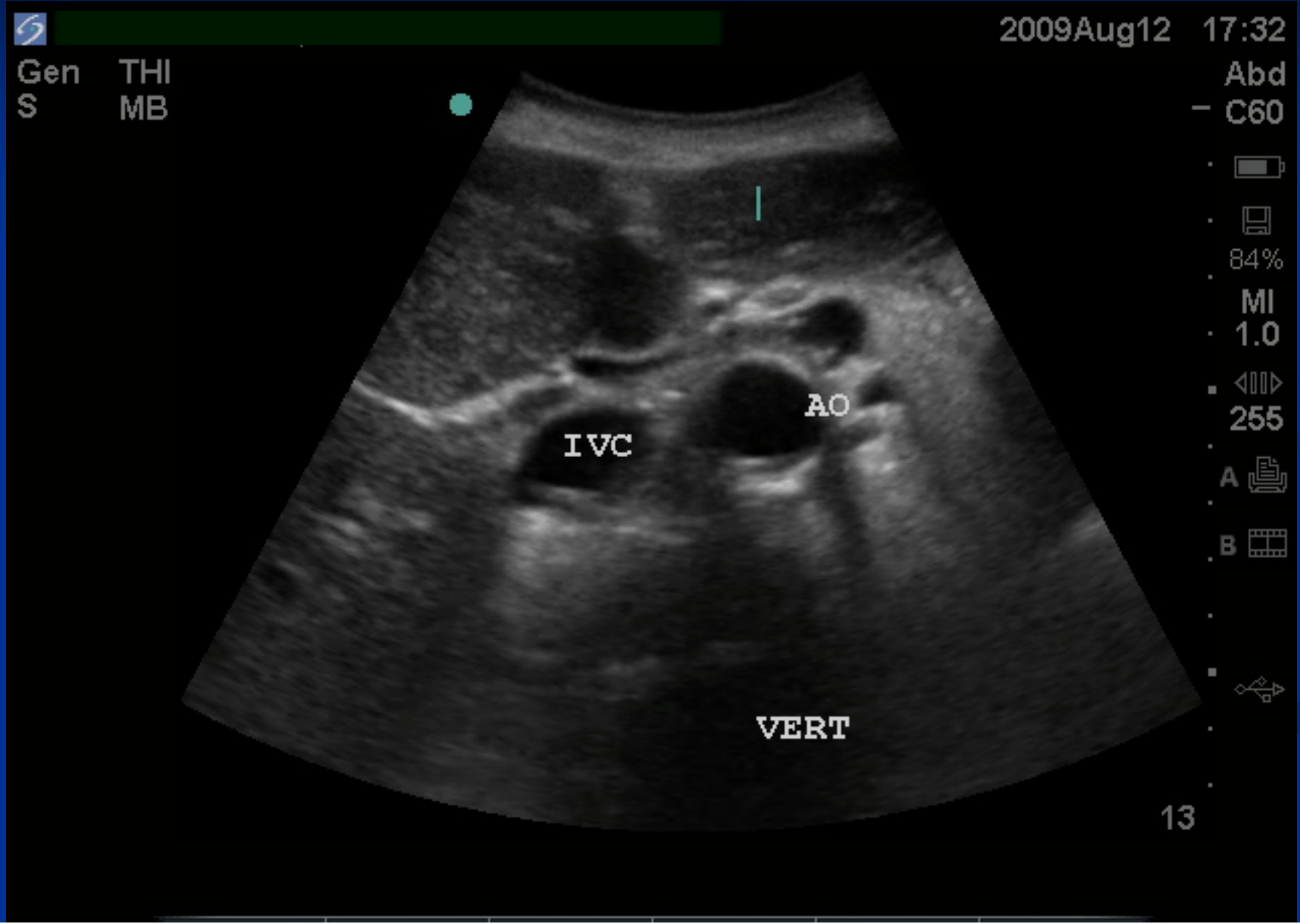
1st view



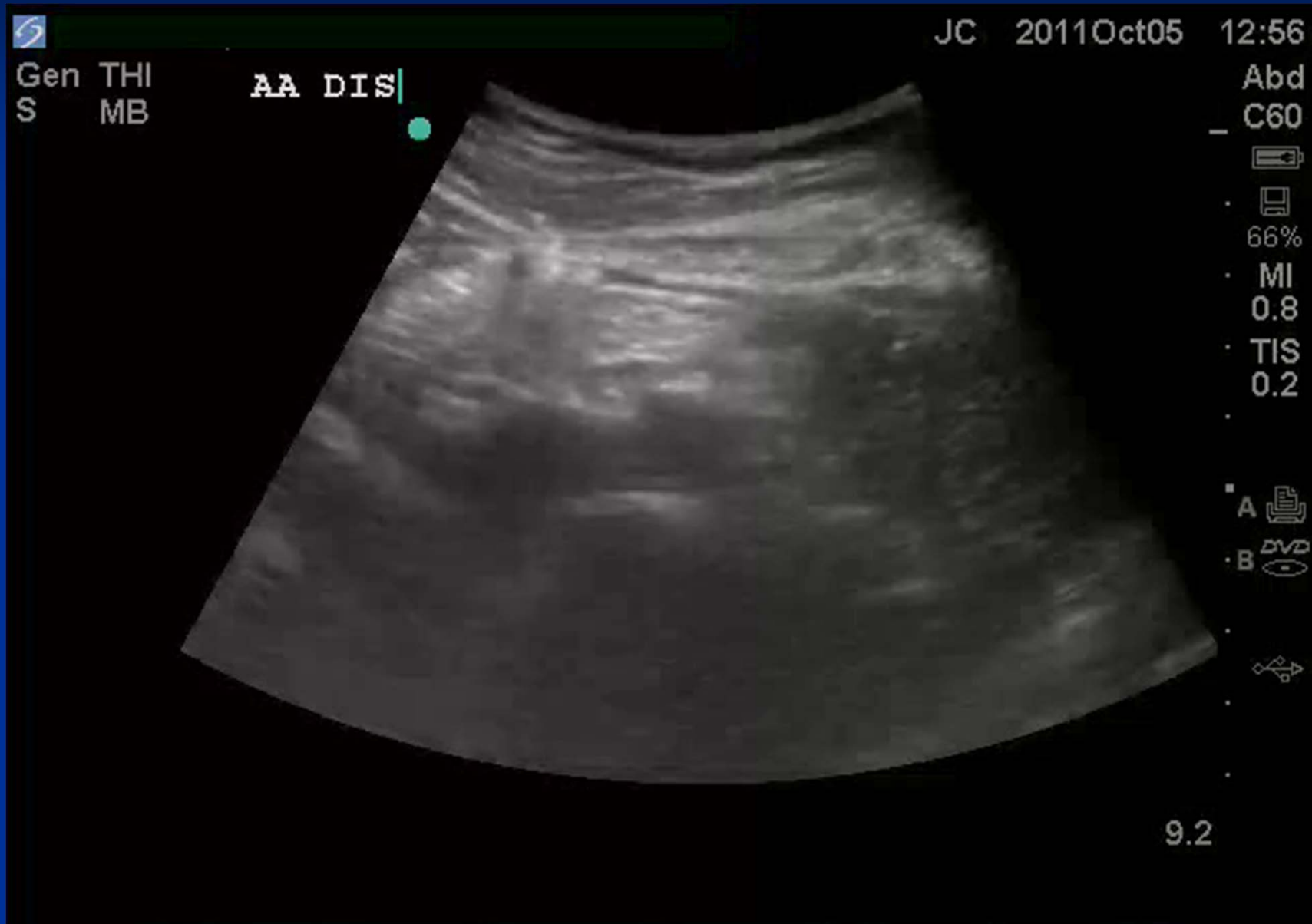1st view



2nd view



3rd view



AAA?

AAA?

No.

Thanks to Dr Juan Chiang for the aorta
bifurcation image.