

# Case Arrest 2

Critical Care Ultrasound Course  
Justin Bowra

# Out of hospital arrest

70 year old male

Severe chest & back pain

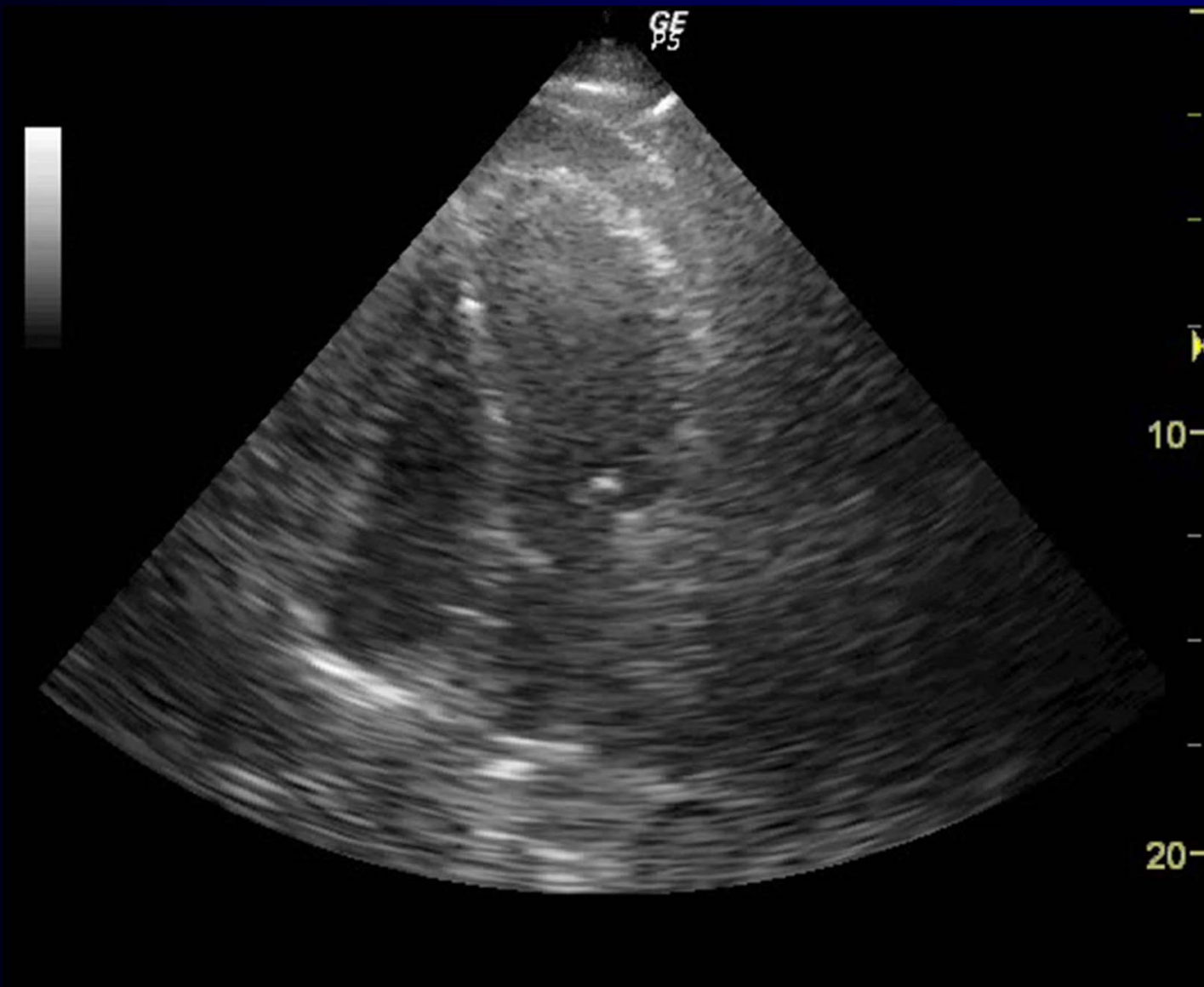
Arrested in back of ambulance

CPR commenced

What will you scan 1<sup>st</sup>?

What will you scan 1<sup>st</sup>?

The heart



What are the 5 questions?

What will you do?

Nearly standstill  
And pericardial stuff  
(Likely dissection)

Pericardiocentesis?  
Operating theatre?  
Cease CPR?