

Emergency Care Institute

Common Hand Conditions

Emergency Guidelines

Acknowledgements

This guide would not have been possible without the contribution of the working party

Lilian Wong - Senior Emergency Physiotherapist

Jade Wong - Senior Hand Therapist

Dr Una Nic Ionmhain - Emergency Physician

Dr Louisa Ng - Emergency Advance Trainee

Dr Mark Rider – Hand Surgery Specialist

Introduction

This document is for all Emergency clinicians managing common hand injuries or hand conditions in the Emergency Department (ED).

It is designed as a quick reference guide to assist Emergency clinicians with the diagnosis and emergency management of common hand presentations to the ED. It is NOT intended as a comprehensive guideline for each condition and should not replace clinical reasoning.

This guide does not include wrist, hand or finger fractures which are covered in the ECI's orthopaedic/musculoskeletal guideline.

Table of Contents

CLOSED HAND INJURIES	Page
Acute Carpal Tunnel Syndrome	5
Bony Mallet	7
Central Slip Rupture	9
Closed Pulley Injuries	11
Jersey Finger	13
Radial Nerve Palsy	15
Scapholunate Dissociation	17
Simple Subungual Haematoma	19
Skier's Thumb	21
Tendinous Mallet	23
Triangular Fibrocartilaginous Complex Injury (TFCC)	25
Trigger Finger	27
Ulna Tunnel Syndrome	29
Volar Plate Injuries	31
 DISLOCATIONS	
Distal Interphalangeal Joint (DIPJ) – Digits 2-5	33
Interphalangeal Joint (IPJ) – Thumb	35
Proximal Interphalangeal Joint (PIPJ) Dorsal Dislocation – Digits 2-5	37
Proximal Interphalangeal Joint (DIPJ) Volar Dislocation – Digits 2-5	39
Metacarpal-Phalangeal Joint (MCPJ) – Digits 2-6	41
Metacarpal-Phalangeal Joint (MCPJ) – Thumb	43
Carpometacarpal Joint (CMCJ) – Digits 2-5	45
Carpometacarpal Joint (CMCJ) - Thumb	47
Lunate Dislocation	49
Peri-lunate Dislocation	52
 INFECTIONS	
Deep Palmar Space Infections	55
Felon	57
High Pressure Injection Injury	59
Infectious Tenosynovitis	61
Paronychia	63

Acute Carpal Tunnel Syndrome

Definition

Rapid onset of median neuropathy caused by sudden increase in carpal tunnel pressure

Different to chronic idiopathic carpal tunnel syndrome

Mechanism

Most common cause is trauma resulting in wrist or hand fractures or dislocations

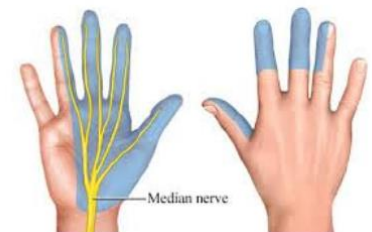
Less common causes include secondary to inflammatory diseases (eg: gout, rheumatoid arthritis), tumours and coagulopathy

Clinical Assessment

- Patients often report acute sensory changes (pain, numbness, pins and needles) in median nerve distribution

Look

- May have mild swelling over wrist
- No muscle atrophy is present with acute carpal tunnel syndrome



Feel

- Reduced sensation in median nerve distribution
- 2 point discrimination test >15mm is abnormal

Move

- Motor movements usually preserved in acute carpal tunnel syndrome
- As neuropathy progresses, may be weakness of the long finger flexors and abductor pollicis brevis

Radiology

Standard wrist-series X-ray useful to rule out underlying fracture or masses

Differentials

- Chronic carpal tunnel syndrome
- Ulna tunnel syndrome
- Cervical radiculopathy
- Forearm or hand compartment syndrome

Emergency Management

- Analgesia
- Short-arm backslab or removable wrist splint
- Elevate
- Immediate referral to hand specialist for surgical decompression

Disposition and Follow-up

- This is a surgical emergency and should be referred immediately to a hand specialist for decompression
- >36hour delay in surgical decompression can result in permanent damage to the median nerve

Pearls and Pitfalls

- Essential to differentiate between acute and chronic (idiopathic) carpal tunnel syndrome. Acute carpal tunnel requires surgical management whereas chronic carpal tunnel syndrome can be managed conservatively
- Key differential is history of trauma, assessment of risk factors (coagulopathy, systemic inflammatory conditions) and time to onset of symptoms
- Physical examination tests for carpal tunnel syndrome such as Tinel's and Phalen's should be avoided as can cause progression of acute neuropathy

Further Reading

Gillig, J., White, S., & Rachel, J. (2016). Acute carpal tunnel syndrome a review of the current literature. *Orthopaedic Clinics of North America*. 47, 599-607

Tosti R., & Ilyas, A. (2012). Acute Carpal Tunnel Syndrome. *Orthopaedic Clinics of North America*. 43, 459-465

Bony Mallet

Definition

Bony injury to terminal extensor mechanism at distal phalanx

Mechanism

Forced flexion to extended DIPJ such as ball hitting fingertip

Clinical Assessment

Look

- Deformity at DIPJ - extensor lag
- Localised swelling of distal phalanx and DIPJ

Feel

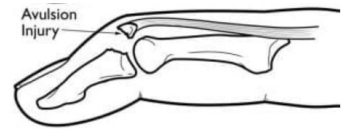
- Maximal tenderness over dorsal DIPJ

Move

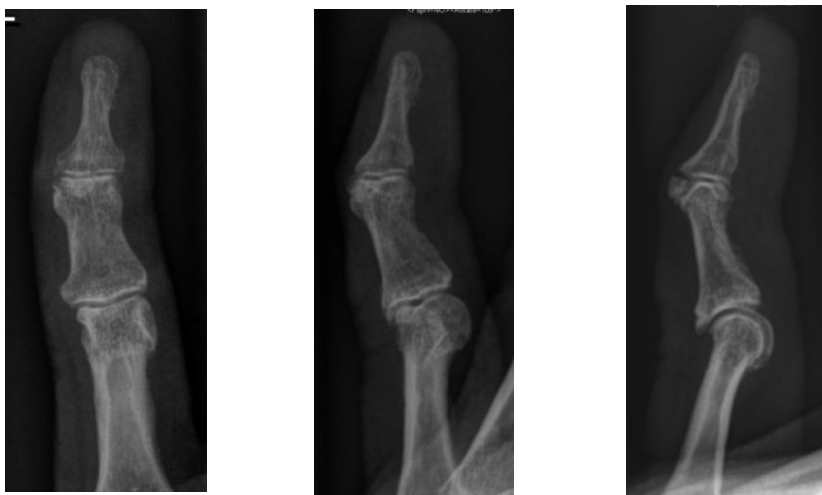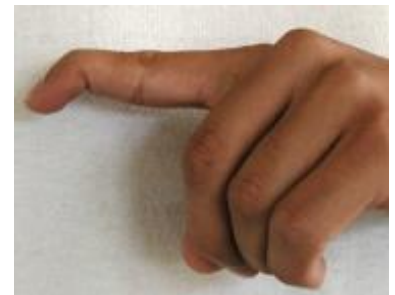- There is NO active extension of DIPJ
- Flexion of DIPJ is preserved

Radiology

Standard finger-series X-rays, lateral view crucial for identifying bony avulsion



<https://littl.com/wp-content/uploads/2019/06/anatomy-mallet-300x246.jpg>



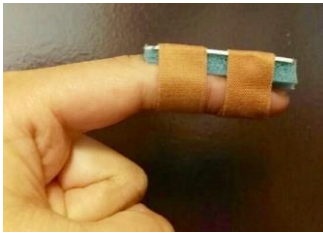Standard finger-series X-ray showing bony mallet to left little finger, visible only on the lateral view

Associated Injuries

- Volar subluxation of DIPJ
- Swan neck deformity

Emergency Management

- Analgesia
- Dorsal digital zimmer splint with finger straight, keeping PIPJ free. Beware to not apply tape too tightly and risk causing digital ischaemia



Disposition and Follow-up

- Avulsion fractures involving $>1/3$ joint surface with DIPJ subluxation will require surgery and should be referred to hand surgeon for follow-up
- Avulsion fractures involving $<1/3$ joint surface with no DIPJ subluxation can be managed conservatively with strict splinting for 6-8 weeks guided by a hand therapist.

Pearls and Pitfalls

- Lateral X-ray is crucial for diagnosing bony mallet
- Lateral X-ray is the only way to differentiate between bony and tendinous mallet
- Untreated mallet injuries can lead to osteo-arthritis of the DIPJ and persistent swan neck deformity

Further Reading

Bassett, R. (2019). Extensor tendon injury of the distal interphalangeal joint (mallet finger) in *UptoDate*.

Lamaris, G., & Matthew, M. (2017). The diagnosis and management of mallet finger injuries. *Hand (NY)*. 12(3), 223-228.

Central Slip Rupture

Definition

Rupture of extensor mechanism at its insertion site at the base of middle phalanx (digits 2-5)

Mechanism

Direct blow onto middle phalanx causing forced PIPJ flexion (jammed finger)

Secondary to volar PIPJ dislocation

Laceration over PIPJ

Clinical Assessment

Look

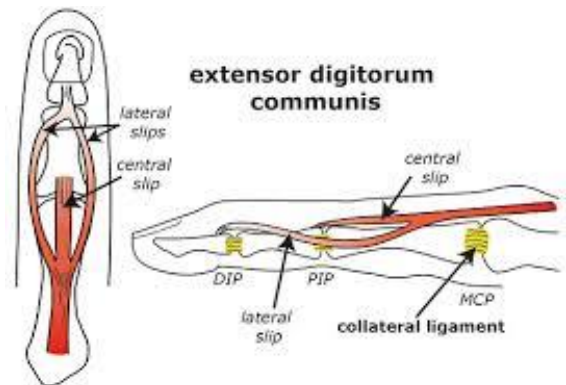
- Swollen digit
- Extensor lag at level of PIPJ
- May present with boutonniere deformity

Feel

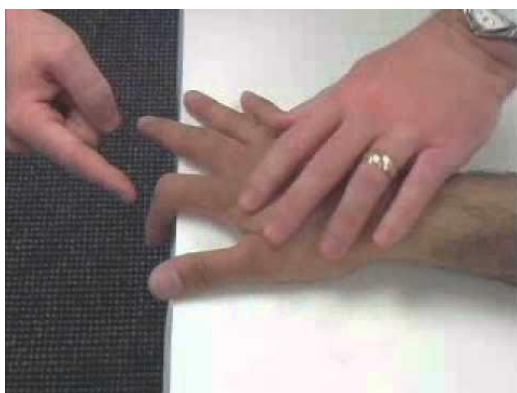- Maximal tenderness over dorsal PIPJ
- May have some tenderness along dorsal proximal phalanx

Move

- There may be reduced or no active extension at PIPJ. This may be a subtle finding.
- Finger flexion of both PIPJ and DIPJ is preserved
- Elson's test – bend PIPJ at 90 degrees over table and extend middle phalanx against resistance. A positive test is weak PIPJ extension and the presence of DIPJ extension (images below)

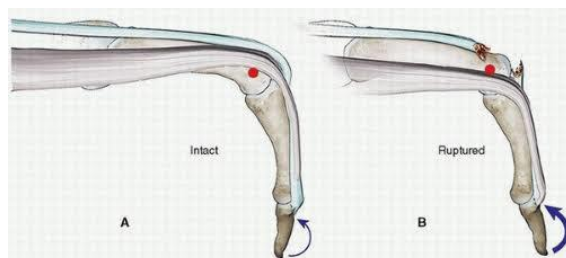


<https://www.startradiology.com/internships/emergency-medicine/hand-fingers/x-hand-fingers/>



<https://www.youtube.com/watch?v=wyHSKgAZ1eA>

Position for Elson's Test

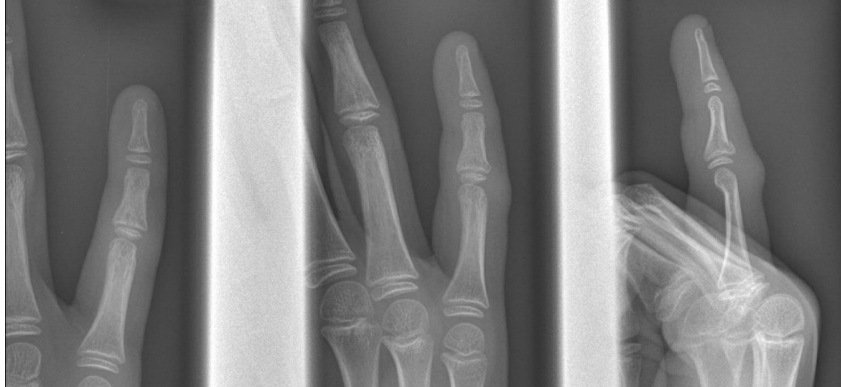

<https://musculoskeletalkey.com/diagnostic-and-therapeutic-approaches-to-the-boutonniere-deformity/>

A positive test is weakness of PIPJ extension and presence of DIPJ extension

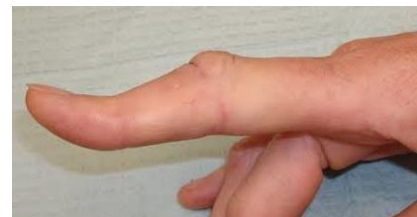Radiology

Standard finger series X-ray, lateral view crucial to assess for avulsion fracture at base of middle phalanx dorsal aspect (images below)



Associated Injuries

- Avulsion fracture at base of middle phalanx, dorsal aspect
- Can occur concurrently with volar PIPJ dislocation
- Can progress to boutonniere deformity (image)



Emergency Management

- Analgesia
- Dorsal digit zimmer splint with MCPJ free. Beware to not apply tape too tightly and risk causing digital ischaemia



Disposition and Follow-up

- All suspected central slip ruptures should be referred to a hand specialist for follow-up
- Central slip ruptures without avulsion fracture are managed conservatively with splinting. Central slip ruptures with a bony component may require surgery
- Missed central slip injuries or delay in treatment can result in boutonniere deformity. This is much harder to treat and can result in long-term impaired function of the affected digit

Pearls and Pitfalls

- In acute central slip rupture, weakness of PIPJ extension may not be apparent as the lateral bands will temporarily act as secondary PIPJ extensors. Elson's test isolates the central slip and should be used to assist diagnosis
- Presence of boutonniere deformity should raise suspicion of underlying central slip injury

Further Reading

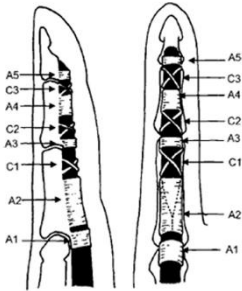
Leggit, J., & Meko, C., (2006). Acute finger injuries: part 1 tendons and ligaments. *American Family Physician*. 73, 810-816.

Closed Pulley Injuries

Definition


Injury to the pulley/s anchoring the long finger flexor tendons to phalanxes

Can be pulley strain or pulley rupture



A = Annular pulley

C – Cruciate pulley



Picture showing crimp grip position in rock-climbing

Mechanism

Sudden overload of pulley system with fingers in crimp grip position (eg: foot slip off wall whilst climbing)

Common in rock climbers and rare in general population

Clinical Assessment

- Patients typically report a “snapping” or “popping” sound at time of injury

Look

- Swollen digit
- May have bruising over volar digit

Feel

- Focal tenderness over the affected pulley

Move

- Active finger flexion of affected digit is limited by pain
- Resisted flexion of affected finger can cause bowstringing if multiple sequential pulleys are ruptured

Radiology

Standard finger-series X-ray to rule out avulsion fractures

Associated Injuries

- Rupture of collateral ligaments of the IPJs
- Phalanx fracture

Emergency Management

- Analgesia
- Dorsal digital zimmer splint to affected digit leaving MCPJ free. Beware to not apply tape too tightly and risk causing digital ischaemia



Disposition and Follow-up

- All closed pulley injuries should be referred to a hand specialist for follow-up
- Pulley strains and rupture of a single pulley can usually be managed conservatively with splinting and exercises guided by a hand therapist
- Multiple pulley ruptures usually require surgical management

Pearls and Pitfalls

- Clinically it is hard to differentiate between a pulley strain, partial tear or complete rupture. All suspected closed pulley injuries should be referred to hand specialist for follow-up.
- Closed pulley injuries rarely occur outside the rock-climbing population
- The thumb also has a pulley system although closed thumb pulley injury is extremely rare

Further Reading

Elizabeth, A., & John, R. (2017). Flexor tendon pulley injuries in rock climbers. *Hand Clinics*. 33, 141–148.

Zafonte, B., Rendulic, D., & Szabo, R. (2014). Flexor Pulley System: Anatomy, Injury and Management. *Journal of Hand Surgery America*. 39(12), 2525-32.

Jersey Finger

Definition

Avulsion of Flexor Digitorum Profundus (FDP) tendon from base of distal phalanx

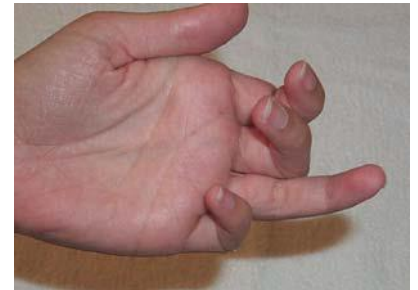Mechanism

Sudden hyperextension of actively flexed finger (eg: finger caught in jersey)

Clinical Assessment

Look

- Swollen finger
- Bruising may be present over volar DIPJ and distal phalanx
- Affected finger usually held in extension



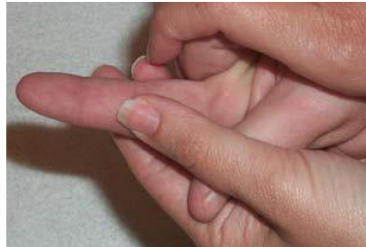<https://www.aafp.org/afp/2006/0301/p810.pdf>

Feel

- Maximal tenderness over volar DIPJ and volar surface of distal phalanx
- May be tender along volar aspect of digit if tendon retraction

Move

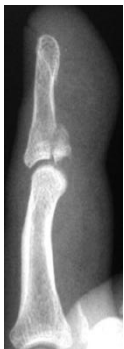- There is NO isolated active flexion of DIPJ. This should be tested with the affected finger held in extension, and all unaffected digits in flexion to eliminate adjacent FDP involvement (image below)



<https://www.aafp.org/afp/2006/0301/p810.pdf>

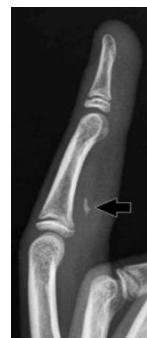Radiology

Standard finger series X-ray, lateral view crucial to assess for avulsion fracture and evidence of tendon retraction



Lateral finger x-ray showing FDP avulsion fracture base of distal phalanx

<https://www.researchgate.net/figure/Lateral-radiograph-showing-a-Leddy-and-Packer-Type-III-FDP-avulsion-fracture-at->



Lateral finger x-ray with bony fleck over volar middle phalanx (black arrow), suggesting FDP tendon retraction

<https://onlinelibrary.wiley.com/doi/full/10.7863/jum.2009.28.3.389>

Associated Injuries

- Avulsion fracture at base of distal phalanx, volar aspect
- Pulley injury

Emergency Management

- Analgesia
- **Dorsal** POSI plaster
- Elevate

Disposition and Follow-up

- All FDP injuries require surgery and must be referred to a hand specialist for follow-up
- Referral within 48hrs to hand specialist is essential as tendon retraction and time from injury both adversely affect prognosis.

Pearls and Pitfalls

- When assessing for DIPJ flexion of one digit, ensure all other digits are straight to eliminate FDP involvement from other digits
- Sometimes there may be minimal pain or tenderness with this injury
- **Dorsal** POSI plaster reduces risk of further tendon retraction compared to the traditional volar POSI

Further Reading

Bachoura, A., Ferikes, AJ., & Lubahn., JD. (2017). A review of mallet finger and jersey finger injuries in the athlete. *Current Reviews in Musculoskeletal Medicine*. 10(1), 1-9.

Bassett, R. (2019). Flexor tendon injury of the distal interphalangeal joint (jersey finger) in *UptoDate*.

Lapegue, F. et al. (2015). Traumatic flexor tendon injuries. *Diagnostic and Interventional Imaging*. 96, 1279-1292.

Leggit, J., & Meko, C., (2006). Acute finger injuries: part 1 tendons and ligaments. *American Family Physician*. 73, 810-816

Radial Nerve Palsy

Definition

Compression neuropathy of radial nerve at either forearm or humeral shaft following fracture

Mechanism

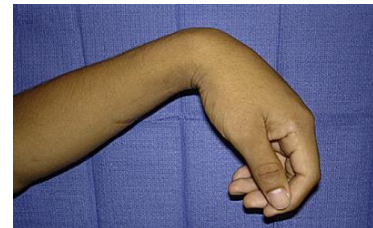
Prolonged direct pressure on forearm eg: falling asleep on forearm

Secondary to humeral shaft fracture

Clinical Assessment

Look

- Classic “wrist drop” presentation
- May have swelling in forearm or wrist

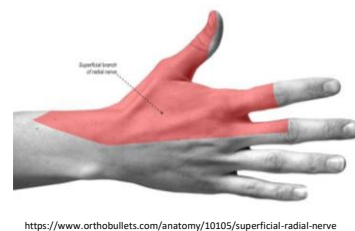

Feel

- Reduced sensation in radial nerve distribution

Move

- No active wrist, thumb or MCPJ extension of digits 2-5
- Weakness with forearm supination



Radiology

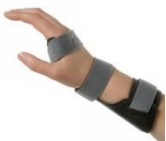X-rays are not required for diagnosis of radial nerve palsy

Differentials

- Cervical radiculopathy, particularly C6-C7
- Mixed brachial plexus neuropathy

Emergency Management

- Removable wrist “cock-up” splint (wrist in slight extension) or short-arm backslab



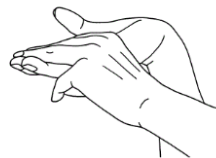
Example of wrist “cock-up” splint

<https://www.sphangerstore.com/manu-forsa-volar-wrist-orthosis-left-medium.html>

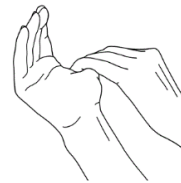- Encourage use hand within splint
- Encourage passive finger extension and thumb abduction stretches

Disposition and Follow-up

- All radial nerve palsy should be referred to a hand specialist for follow-up
- Most cases of radial nerve palsy are transient and will self-resolve
- Supportive therapies such as splinting and passive wrist/finger/thumb stretches are important during the recovery stage to prevent secondary problems like contractures developing.



©PhvsoToolsLtd



©PhvsoToolsLtd

Pearls and Pitfalls

- When placed in a wrist cock-up splint, patients with radial nerve palsy are able to use their lumbricals and intrinsic muscles to grip, enabling some level of daily function
- Contractures, particularly of the thumb webspace, can develop very quickly. Encouraging patients to passively stretch their fingers into extension and thumb into abduction will assist in preventing this
- Neurological examination is key to differentiate between ulna tunnel syndrome, cervical radiculopathy and mixed brachial plexus neuropathy

Further Reading

Carlson, N. & Logigian, E. (1999). Radial neuropathy. *Neurological Clinics*. 17(3), 499-523.

Rutkove, S. (2019). Overview of upper extremity peripheral nerve syndromes in *UptoDate*.

Scapholunate Dissociation

Definition

Complete rupture to the scapholunate ligament (SLL) in wrist

Mechanism

Typically fall onto hyperextended wrist

Clinical Assessment

- Patients often complain of subjective wrist instability, wrist weakness or clicking and catching with movement

Look

- Swollen wrist, especially dorsally

Feel

- Maximal tenderness at scapho-lunate joint, particularly dorsal surface just distal to lister's tubercle
- Can also be tender at proximal anatomical snuffbox

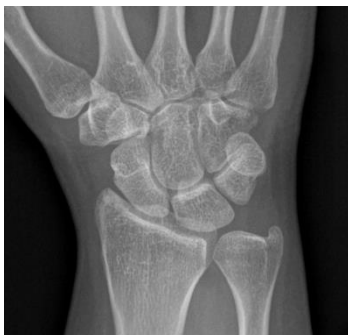Move

- Wrist extension and radial deviation are limited by pain
- Movement can be associated with "clunk"

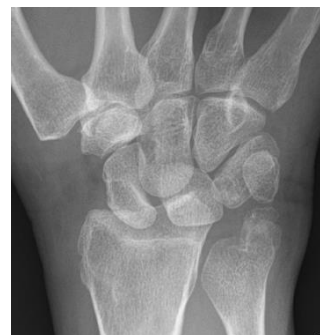Radiology

Standard wrist series X-ray

- >3mm widening between scaphoid and lunate (Terry-Thomas sign) indicates rupture of SLL
- Inclusion of "clenched-fist" view can highlight interval between scaphoid and lunate



Normal wrist (ap) x-ray



Wrist (ap) x-ray showing widened interval between scaphoid and lunate

Associated Injuries

- Distal radius fracture
- Scaphoid fracture
- Concurrent tears of adjacent carpal ligaments

Emergency Management

- Analgesia
- Short-arm volar backslab or removable wrist splint
- Elevate

Disposition and Follow-up

- All scapholunate dissociation injuries require surgical management and should be referred to a hand specialist
- Incomplete SLL tears (or sprain) can often be managed conservatively with splinting and exercises guided by a hand therapist
- Delay in treatment for scapholunate dissociation can lead to wrist arthritis, scapho-lunate advanced collapse (SLAC) and poor functional outcomes

Pearls and Pitfalls

- The Terry-Thomas sign may not be present with incomplete SLL tears (sprain). If clinical examination is suspicious for SLL injury, refer to hand specialist for further evaluation

Further Reading

Bogges, BR. (2019). Evaluation of the adult with acute wrist pain in *Uptodate*.

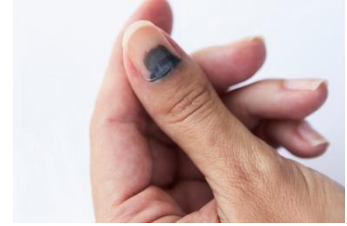Lau, S., Swarna, S., & Tamvakopoulos, G. (2009). Scapholunate dissociation: an overview of the clinical entity and current treatment options. *European Journal of Orthopaedic Surgery & Traumatology*. 19(6), 377-385.

Simple Subungual Haematoma

Definition

Collection of blood underneath nail plate

Simple refers to subungual haematoma in absence of associated nail fold or digit injury



https://www.health.harvard.edu/a_to_z/nail-trauma-a-to-z

Mechanism

Blow or crush injury to distal phalanx causing bleeding from nail bed

Clinical Assessment

Look

- Discolouration underneath the nail plate which is blue black in colour
- Swelling to distal phalanx

Feel

- Focal tender over nail plate and distal phalanx. Often described as “throbbing pain.”

Move

- There may be reduced DIPJ movement secondary to pain and swelling

Radiology

Must have standard finger-series X-ray to rule out distal phalanx fractures, in particular for subungual haematoma involving >50% of nail plate surface area

Associated Injuries

- Distal phalanx fractures
- Mallet injury
- Nail bed laceration
- Nail plate avulsion

Emergency Management

- Analgesia
- For subungual haematoma involving <50% of nail plate surface, manage conservatively with advice for elevation and short-term digital splint for comfort
- For subungual haematoma involving >50% of nail plate surface or significant discomfort for patient, consider trephination of nail plate using fine needle to drain blood.

Disposition and Follow-up

- Majority of patients have good outcome and can be managed by a GP
- There may be nail loss and/or nail deformity in the short-term, although this should resolve once a new nail plate has regrown
- If associated with distal phalanx fracture, nail bed laceration, nail bed avulsion or haematoma involving 100% nail plate surface, refer to hand specialist for consideration of surgery

Pearls and Pitfalls

- Trephination is most effective in the first 24 hours post injury prior to blood clotting
- Must assess for concomitant injuries (eg: distal phalanx fracture, nail bed laceration) prior to managing as isolated simple subungual haematoma

Further Reading

Batrick, N., Hashemi, K., & Freij, R. (2003). Treatment of uncomplicated subungual haematoma. *Emergency Medicine Journal*. 20(1), 65.

Dean, B., Becker, G., & Little, C. (2012). The management of the acute traumatic subungual haematoma: a systematic review. *Hand Surgery*. 17(1), 151-154.

Fastle, R., & Bothner, J. (2018). Subungual Haematoma in *UpToDate*

Skier's Thumb

Definition

Acute injury to ulna collateral ligament (UCL) at MCPJ of thumb

Mechanism

Forced abduction of thumb (eg: against ski-pole)

Clinical Assessment

Look

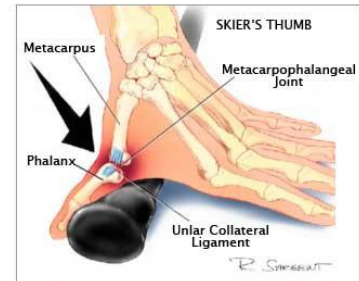
- Localized swelling to MCPJ of thumb
- Can have bruising over MCPJ of thumb

Feel

- Maximal tenderness over UCL at MCPJ of thumb

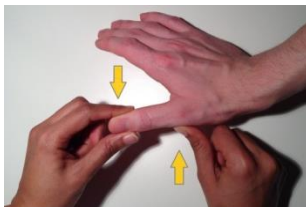
Move

- Pain with thumb MCPJ movement, especially abduction
- IPJ movement should be preserved
- Perform UCL stress test at both MCPJ in 0 degrees extension and 30 degrees flexion. Considered positive if pain or laxity compared with uninjured side



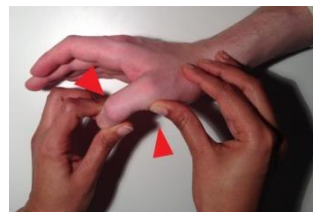
MECHANISM OF INJURY RESULTING IN A SKIER'S THUMB

https://www.physio-pedia.com/Skier%27s_thumb



https://www.physio-pedia.com/Skier%27s_thumb

Testing with MCPJ in 0 degrees

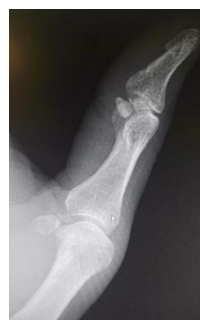
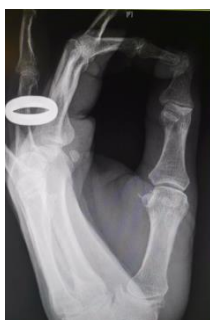
https://www.physio-pedia.com/Skier%27s_thumb

Testing with MCPJ at 30

Radiology

Standard thumb X-ray to assess for associated avulsion fracture



Thumb X-ray showing UCL avulsion fracture at base of proximal phalanx on ulna side

Associated Injuries

- Avulsion fracture base of proximal phalanx on ulna side
- Stener Lesion – serious complication associated with complete (grade III) UCL ruptures whereby the UCL is trapped between adductor pollicis aponeurosis and bone, preventing healing.

Emergency Management

- Analgesia
- Thumb spica plaster keeping IPJ of thumb free
- Elevate

Disposition and Follow-up

- All suspected UCL sprains/ruptures should be referred to hand specialist for review
- UCL ruptures associated with Stener lesion and avulsion fracture will require surgery
- Incomplete UCL ruptures are usually managed conservatively with splinting and exercises guided by a hand therapist

Pearls and Pitfalls

- UCL rupture can be partial or complete
- Gamekeepers' thumb refers to chronic injury of the UCL and is different to Skier's thumb

Further Reading

Gammons, M. (2019). Ulna collateral ligament injury (Gamekeeper's or Skier's thumb) in *Uptodate*.

Mahajan, M., & Rhemrev, S.J. (2013). Rupture of the ulnar collateral ligament of the thumb – a review. *International Journal of Emergency Medicine*. 6:31, 1-6.

Tendinous Mallet

Definition

Rupture of terminal extensor tendon at dorsal aspect of distal phalanx

Mechanism

Forced flexion to DIPJ such as ball hitting fingertip

Clinical Assessment

Look

- Deformity at DIPJ - extensor lag
- Localised swelling of distal phalanx and DIPJ

Feel

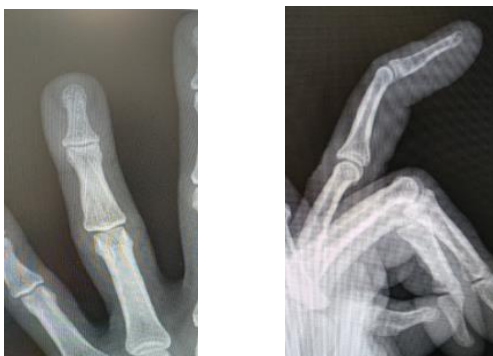- Maximal tenderness over dorsal DIPJ
- May be tender along dorsal aspect of digit if tendon retraction

Move

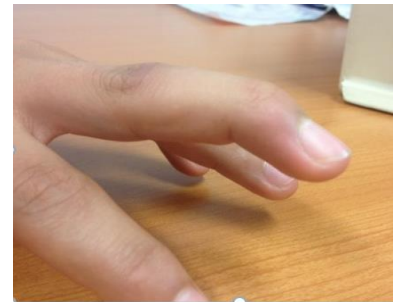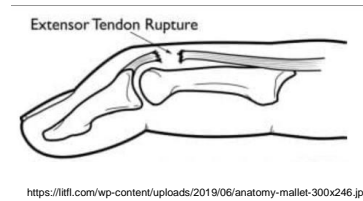
- There is NO active extension of DIPJ
- Flexion of DIPJ is preserved

Radiology

Standard finger-series X-ray, lateral view crucial to differentiate with bony mallet



Finger X-ray showing tendinous mallet to left ring finger

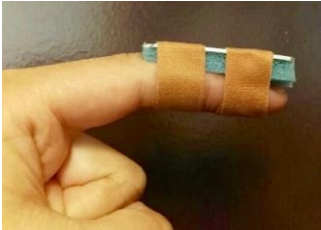

Associated Injuries

- DIPJ subluxation
- Swan neck deformity

Emergency Management

- Analgesia
- Dorsal digital zimmer splint with finger straight, keeping PIPJ free. Beware to not apply tape too tightly and risk causing digital ischaemia.



Disposition and Follow-up

- Tendinous mallet with volar subluxation of DIPJ requires referral to hand specialist
- Tendinous mallet with no volar subluxation of DIPJ requires strict splinting for 10-12 weeks and should be referred to a hand therapist

Pearls and Pitfalls

- Lateral finger X-ray is the only way to differentiate between bony and tendinous mallet
- Untreated mallet injuries can lead to osteo-arthritis of the DIPJ and swan neck deformity

Further Reading

Bassett, R. (2019). Extensor tendon injury of the distal interphalangeal joint (mallet finger) in *UptoDate*.

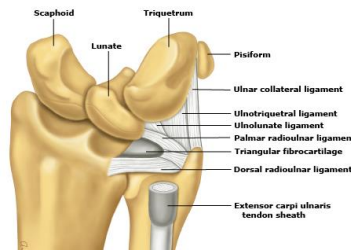
Lamaris, G., & Matthew, M. (2017). The diagnosis and management of mallet finger injuries. *Hand (NY)*. 12(3), 223-228.

Triangular Fibrocartilagenous Complex (TFCC) Injury

Definition

Injury to the TFCC of the wrist

Can be sprain or tear



TFCC complex is comprised of multiple ligaments and the triangular fibrocartilage

<https://somepomed.org/articulos/contents/mobipreview.htm?3/5/3156>

Mechanism

Can be traumatic (usually following FOOSH injury) or degenerative

Clinical Assessment

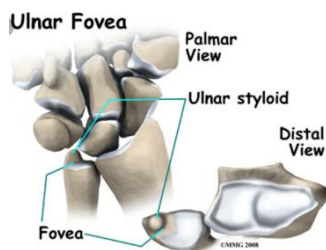
- Patients will report ulna-sided wrist pain which is worse with activities like opening/closing taps pushing up from a chair or lifting heavy objects
- Patients may also complain of clicking in the wrist

Look

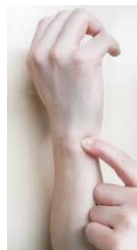- Ulna sided wrist swelling

Feel

- Focal tenderness of the ulna fovea (space between extensor carpi and flexor carpi ulnaris)



<https://eorthopod.com/triangular-fibrocartilage-complex-tfcc-injuries/>



Move

- Painful movement of wrist, in particular ulna deviation and/or pronation
- Combined axial loading of wrist in extension reproduces pain

Radiology

Standard wrist-series X-ray to rule out DRUJ (distal radio-ulna joint) injuries and fracture

Differentials

- DRUJ instability
- Extensor carpi ulnaris (ECU) tendonitis
- Ulna styloid fracture

Emergency Management

- Oral analgesia
- Short-arm backslab or wrist splint
- Advice rest and avoid gripping activities

Disposition and Follow-up

- Minor TFCC injuries can be managed by a GP or hand therapist with advice to rest and splint for comfort
- TFCC injuries associated with trauma, are persistent and causing functional impairment should be referred to a hand specialist for review

Pearls and Pitfalls

- TFCC injuries represent one of the most common causes of ulna-sided wrist pain and should always be considered as a possible diagnosis or differential in patients with ulna wrist pain
- TFCC injuries often occur with distal radius fractures. Persistent ulna-sided wrist pain in a patient with recent distal radius fracture should trigger suspicion of TFCC injury
- Focal tenderness of the ulna fovea is the most specific objective indicator of a TFCC injury

Further Reading

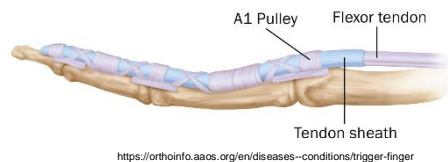
Atzei, A., & Luchetti, R. (2011). Foveal TFCC Tear Classification and Treatment. *Hand Clinics*. 27, 263–272.

Trigger Finger

Definition

Also known as stenosing flexor tenosynovitis

The catching of the long finger flexors at the A1 pulley (located over volar aspect of metacarpal-phalangeal joint) during active finger flexion



Mechanism

Caused by pathology between flexor synovial sheath and underlying tendon which impedes smooth gliding of the long flexors during flexion movement

Exact mechanism is unclear although can be associated with overuse or repetitive finger movements

Clinical Assessment

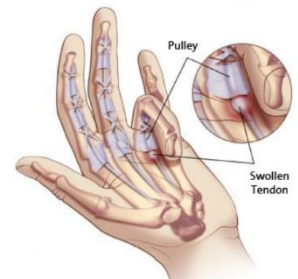
- Patients report sensation of catching, clicking or locking of affected digit which is often worse first thing in the morning

Look

- Swelling over volar aspect of metacarpal phalangeal joint (location of A1 pulley)
- If severe, digit may be locked in fixed flexion position

Feel

- Pain over A1 pulley
- May be palpable click over A1 pulley



Move

- Flexion of digit is associated with painful catching (triggering) at the A1 pulley
- There may be locking of digit as patient tries to actively extend digit from a flexed position, requiring digit to be passively straightened. In late stages, there may be fixed flexion contracture of digit

Radiology

Imaging is not required for the diagnosis of trigger finger

Emergency Management

- Analgesia
- Can consider dorsal finger splint to hold finger straight. This should only be used as a short-term measure for comfort until review by a hand therapist for proper splint

Disposition and Follow-up

- Trigger finger without locking or flexion contracture should be referred to a hand therapist for trial of conservative management and splinting. Ultrasound guided steroid injection can be considered for milder cases.
- Trigger finger with locking or flexion contracture should be referred to a hand specialist for consideration of surgery.

Pearls and Pitfalls

- Trigger finger can occur in paediatric populations with the thumb being most commonly affected digit.
- Triggering is usually worst first thing in the morning. Wearing a splint fabricated by hand therapists whilst sleeping at night can help prevent this.

Further Reading

Giugale, J., & Fowler, J. (2015) Trigger finger adult and paediatric treatment. *Orthopaedic Clinic North America*. 46, 561-569

Ulna Tunnel Syndrome

Definition

Compression neuropathy of ulna nerve at level of the wrist

Mechanism

Repetitive trauma eg: using jackhammer

Chronic pressure over ulna aspect of hand eg: handlebars on bicycle

Following acute hook of hamate fracture

Space occupying lesion

Clinical Assessment

- Patients often report sensory changes (pain, numbness P+N) along ulna nerve distribution
- May complain of hand or grip weakness

Look

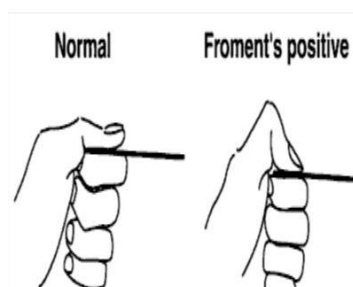
- Muscle wasting: Hypothenar, interossei, dorsal thumb webspace
- May have clawing of ring and little finger if prolonged compression
- Swelling if associated with hook of hamate fracture

Feel

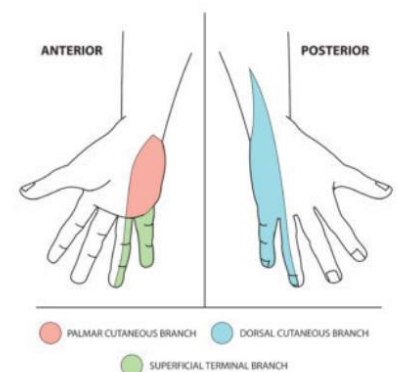
- Reduced sensation in ulna nerve distribution
- Point tenderness over hook of hamate if fractured
- Palpable mass can indicate space occupying lesion

Move

- Weakness of interossei and inability to cross fingers
- Weakness in thumb adduction which can be tested using Froment's sign (image below)



<https://teachneuro.blogspot.com/2012/04/froments-sign.html?m=0>



Radiology

Standard wrist-series X-rays if suspect underlying hamate fracture

Differentials

- Carpal tunnel syndrome
- Cervical radiculopathy
- Cubital tunnel syndrome
- Mixed brachial plexus neuropathy

Emergency Management

- Analgesia
- Wrist splint or short-arm plaster if associated with hook of hamate fracture

Disposition and Follow-up

- All ulna tunnel syndromes should be referred to a hand specialist for follow-up
- Treatment depends on cause and can include conservative management through splinting or surgery for removal of space occupying lesions

Pearls and Pitfalls

- Ulna tunnel syndrome can present with either isolated motor and sensory loss, or combination of both.
- Neurological examination is key to differentiate between ulna tunnel syndrome, cervical radiculopathy and mixed brachial plexus neuropathy

Further Reading

Bachoura, A., & Jacoby, S. (2012). Ulnar Tunnel Syndrome. *Orthopaedic Clinics North America*. 42, 467-474.

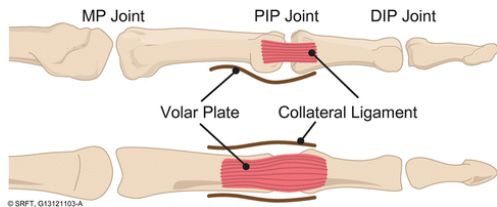
Chen, S., & Tsai, T. (2014). Ulnar Tunnel Syndrome. *Journal of Hand Surgery America*. 39, 571-579.

Volar Plate Injuries

Definition

Injury to the volar plate over PIPJ

Can be volar plate sprain or volar plate avulsion #



https://link.springer.com/chapter/10.1007/978-1-4471-6554-5_8

Mechanism

Forced hyperextension of finger (eg: finger bent backwards by ball)

Secondary injury to dorsal dislocation of PIPJ

Clinical Assessment

Look

- Swollen finger, especially at level of PIPJ
- May be bruising over volar aspect of PIPJ

Feel

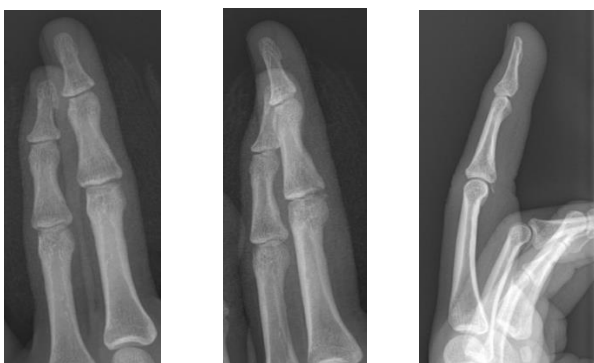
- Maximal tenderness over volar aspect of PIPJ
- May be tender over both radial and ulna collateral ligaments at PIPJ

Move

- Reduced active flexion and extension of PIPJ due to pain
- Passive extension of PIPJ very painful

Radiology

Standard finger series X-ray, lateral view crucial to assess for associated avulsion #



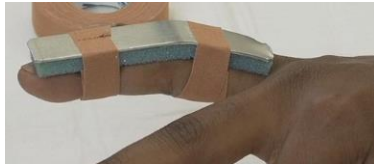Finger-series X-ray showing volar plate avulsion fracture of left middle finger, visible only on the lateral view

Associated Injuries

- Volar plate avulsion fracture
- Collateral ligament injury at PIPJ

Emergency Management

- Analgesia
- Dorsal finger splint with PIPJ slightly flexed to protect volar plate. Beware to not apply tape too tightly and risk causing digital ischaemia.



Disposition and Follow-up

- Volar plate sprain and small volar plate avulsion fractures can be managed by GP and hand therapist
- Volar plate avulsion fracture involving >1/3 articular surface or with unstable PIPJ should be referred to a hand specialist for management

Pearls and Pitfalls

- The most common error with managing volar plate injuries is prolonged splinting. This causes finger stiffness which is much harder to treat
- Finger flexion exercises should commence within a few days of injury and splinting should not be for more than 1 week. Consider weaning to buddy strap to prevent stiffness and avoid hyperextending finger
- It is crucial to take finger series X-ray, particularly lateral view, to assess for associated avulsion fracture

Further Reading

Bassett, R. (2019). Middle phalanx fractures in *Uptodate*

Body, R. (2005). Early mobilization for volar plate avulsion fractures – best evidence topic reports. *Emergency Medicine Journal*. 22, 504-509.

Distal Interphalangeal Joint (DIPJ) Dislocation Digits 2-5

Definition

Dorsal or volar (less common) translation of distal phalanx relative to digit

Mechanism

Direct impact onto fingertip such as with catching sports or landing on digit from fall

Clinical Assessment

Look

- Step deformity at level of DIPJ
- Swollen digit and localised bruising

Feel

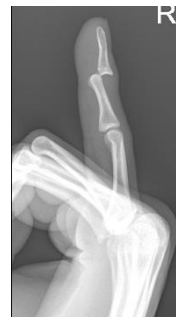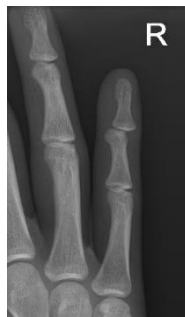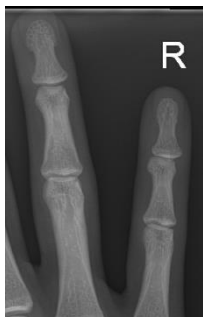- Step deformity palpable at DIPJ
- Maximal tenderness to DIPJ and base of distal phalanx
- May have altered sensation to tip of finger

Move

- No active flexion or extension of DIPJ
- Movement at PIPJ is preserved

Radiology

Standard finger-series X-ray, lateral view crucial to confirm direction of dislocation and assess for associated avulsion fractures



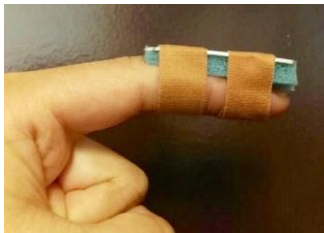X-rays showing dorsal DIPJ dislocation of right little finger

Associated Injuries

- Fracture of distal phalanx
- Rupture of FDP with dorsal DIPJ dislocation
- DIPJ volar plate injury
- Nail-bed injuries

Emergency Management

- Analgesia
- Ring block to affected finger
- Closed reduction
 - Longitudinal traction
 - For dorsal dislocation, simultaneously gently hyper-extend joint and apply direct pressure over dorsal aspect of distal phalanx until reduction achieved
 - For volar dislocation, simultaneously gently hyper-flex joint and apply direct pressure over volar aspect of distal phalanx until reduction achieved
 - Check for clinical relocation by asking patient to actively move DIPJ
- Repeat X-ray to assess post-reduction position
- Apply dorsal digital zimmer splint to affected finger leaving PIPJ free. Beware to not apply tape too tightly and risk causing digital ischaemia.



Disposition and Follow-up

- All DIPJ dislocations should be referred to hand specialist for follow-up

Pearls and Pitfalls

- DIPJ dislocations can be difficult to reduce, particularly if volar plate is trapped inside the joint. Longitudinal traction for dis-impaction is essential for successful reduction.
- In cases of failed reduction, splint digit in position of comfort and immediately refer to hand specialist

Further Reading

Joshi, S. (2019). Digit dislocation reduction in *Uptodate*

Leggit, JC., & Meko, C. (2006). Acute finger injuries: part II. Fractures, dislocations, and thumb injuries. *American Family Physician*. 73, 827–834, 839.

Interphalangeal Joint (IPJ) Dislocation of Thumb

Definition

Dorsal or volar (less common) translation of distal phalanx relative to proximal phalanx of thumb

Mechanism

Direct impact onto distal phalanx of thumb such as through catching sports or landing on thumb from fall

Clinical Assessment

Look

- Step deformity at IPJ level of thumb
- Swollen thumb and localised bruising

Feel

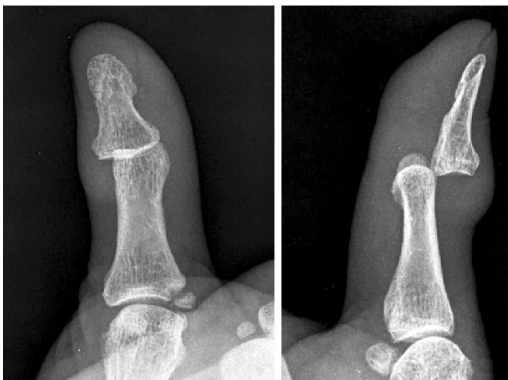
- Step deformity palpable at IPJ of thumb
- Maximal tenderness to IPJ of thumb
- May have altered sensation to tip of thumb

Move

- No active flexion or extension of thumb IPJ
- Thumb MCPJ movement is preserved

Radiology

Standard thumb X-ray, lateral view crucial to confirm direction of dislocation and assess for associated avulsion fractures



Thumb X-ray showing dorsal IPJ dislocation of right thumb

Associated Injuries

- Distal phalanx fracture
- IPJ collateral ligament injury
- Rupture of FPL
- Volar plate injury
- Nail bed injury

Emergency Management

- Oral analgesia
- Ring block to thumb
- Closed reduction
 - Longitudinal traction
 - For dorsal dislocation, simultaneously gently hyper-extend joint and apply direct pressure over dorsal aspect of distal phalanx until reduction achieved
 - For volar dislocation, simultaneously gently hyper-flex joint and apply direct pressure over volar aspect of distal phalanx until reduction achieved
 - Check for clinical relocation by asking patient to actively move thumb IPJ
- Apply thumb spica plaster and elevate
- Repeat X-ray to assess post-reduction position

Disposition and Follow-up

- All thumb IPJ dislocations should be referred to a hand specialist for follow-up
- IPJ dislocations which are clinically stable following relocation are usually managed conservatively with splinting and exercises guided by hand therapist
- Operative management may be required if failed reduction, associated with large fragment bony avulsion or rupture of collateral ligaments causing IPJ instability

Pearls and Pitfalls

- Thumb IPJ dislocations can be difficult to reduce, particularly if the volar plate or FDP is trapped inside the joint. Longitudinal traction for dis-impaction is essential for successful relocation
- In cases of failed reduction, apply thumb spica plaster and refer immediately to hand specialist

Further Reading

Joshi, S. (2019). Digit dislocation reduction in *Uptodate*.

Leggit, JC., & Meko, C. (2006). Acute finger injuries: part II. Fractures, dislocations, and thumb injuries. *American Family Physician*. 73, 827–834, 839.

Proximal Interphalangeal Joint (PIPJ) Dorsal Dislocation (Digits 2-5)

Definition

Dorsal translation of middle phalanx relative to proximal phalanx of digits 2-5

Mechanism

Direct axial loading force on extended finger such as when catching a ball or falling onto finger

Clinical Assessment

Look

- Step deformity at level of PIPJ
- Swollen digit and localised bruising

Feel

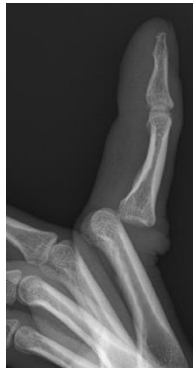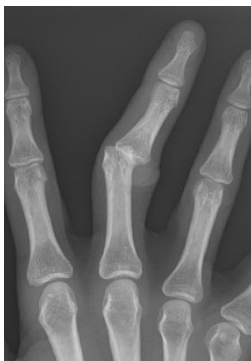- Step deformity palpable at level of PIPJ of digit
- Maximal tenderness at PIPJ and base of middle phalanx
- May have altered sensation to digit

Move

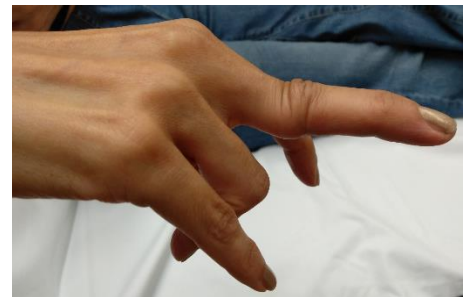- There is no active flexion or extension at PIPJ
- DIPJ movement is pain limited
- MCPJ movement is preserved

Radiology

Standard finger-series X-ray, lateral view crucial to confirm direction of dislocation and assess for associated avulsion fracture



X-ray showing dorsal PIPJ dislocation of right middle finger

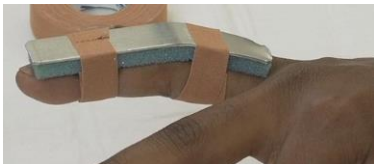

Associated Injuries

- Volar plate avulsion fracture
- Volar plate injury
- PIPJ collateral ligament injury

Emergency Management

- Oral analgesia
- Ring block to affected digit
- Closed reduction
 - Longitudinal traction
 - Simultaneously gently hyper-extend joint and apply direct pressure over dorsal aspect of middle phalanx until reduction achieved
 - Check for clinical relocation by asking patient to move PIPJ
- Apply dorsal splint to digit with PIPJ slightly flexed to protect volar plate. Beware to not apply tape too tightly and risk causing digital ischaemia.



- Repeat X-ray to assess post-reduction position and assess for associated fractures

Disposition and Follow-up

- All PIPJ dislocations should be referred to a hand specialist for follow-up
- PIPJ dislocations that are clinically stable or with small volar plate avulsion fractures are usually managed conservatively with splinting and exercises guided by a hand therapist
- Operative management may be required if failed reduction, associated with large volar plate avulsion fracture or rupture of collateral ligaments causing PIPJ instability

Pearls and Pitfalls

- Dorsal PIPJ dislocations are the most common type of digital dislocation
- Dorsal PIPJ dislocations are generally easily reducible. If reduction is difficult, usually associated with volar plate being trapped inside the joint or large bony fragment blocking reduction
- In cases of failed reduction, apply digital splint in position of comfort and refer immediately to a hand specialist

Further Reading

Joshi, S. (2019). Digit dislocation reduction in *Uptodate*.

Leggit, JC., & Meko, C. (2006). Acute finger injuries: part II. Fractures, dislocations, and thumb injuries. *American Family Physician*. 73, 827–834, 839.

Proximal Interphalangeal Joint (PIPJ) Volar Dislocation (Digits 2-5)

Definition

Volar translation of middle phalanx relative to proximal phalanx of digits 2-5

Mechanism

Direct axial loading force on flexed finger (eg: getting finger caught in spinning clothes dryer)

Clinical Assessment

Look

- Step deformity over PIPJ
- Swollen digit and localised bruising

Feel

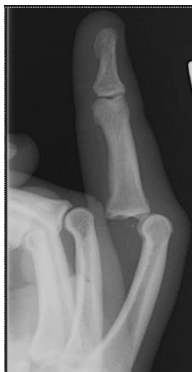- Step deformity palpable at level of PIPJ of digit
- Maximal tenderness at PIPJ and base of middle phalanx
- May have altered sensation to digit

Move

- There is no active flexion or extension at PIPJ
- DIPJ movement is pain limited
- MCPJ movement is preserved

Radiology

Standard finger-series X-ray, lateral view crucial to confirm direction of dislocation and assess for associated avulsion fracture



Lateral X-ray showing volar PIPJ dislocation of right index finger

<https://www.orthobullets.com/hand/6038/phalanx->

Associated Injuries

- Central slip rupture
- Avulsion fracture to base of middle phalanx
- PIPJ collateral ligament injury

Emergency Management

- Oral analgesia
- Digital ring block to affected finger
- Closed reduction
 - Keep MCPJ of affected finger flexed to 90 degrees (relaxes lateral bands)
 - Longitudinal traction and simultaneously hyper-flex joint and apply direct pressure over volar aspect of middle phalanx until reduction achieved
 - Check for clinical relocation by asking patient to move PIPJ
- Apply dorsal zimmer splint to affected digit with finger straight, leaving MCPJ free. Beware to not apply tape too tightly and risk causing digital ischaemia.



- Repeat X-ray to assess post-reduction position and assess for associated fractures

Disposition and Follow-up

- All PIPJ dislocations must be referred to a hand specialist for follow-up
- Volar PIPJ dislocations with an intact central slip, no associated avulsion fracture and clinical stable are usually managed conservatively with splinting and exercises guided by hand therapist
- Operative management will be required in cases of failed reduction, avulsion fractures disrupting extensor mechanism or rupture of collateral ligaments causing PIPJ instability

Pearls and Pitfalls

- Volar PIPJ dislocations are a rare injury and are difficult to reduce
- Trapping of the extensor tendon and lateral bands in the articular surface can prevent successful closed reduction even if effective longitudinal traction is applied
- In cases of failed reduction, apply digital splint in position of comfort and refer immediately to a hand specialist

Further Reading

Borchers, J., & Best, T. (2012). Common finger fractures and dislocations. *American Family Physician*. 85(8), 805-810.

Leggit, J., & Meko, C. (2006). Acute finger injuries: part II. Fractures, dislocations, and thumb injuries. *American Family Physician*. 73, 827–834, 839.

Metacarpal-Phalangeal Joint (MCPJ) Dislocation (Digits 2-5)

Definition

Dorsal or volar (rare) translation of proximal phalanx relative to metacarpal digits 2-5

Mechanism

High energy trauma resulting in forceful hyperflexion or hyperextension at MCPJ (eg:) falling on outstretched or flexed hand

Clinical Assessment

Look

- Deformity at level of MCPJ with fingers typically held in flexed position
- Obvious prominence at “knuckle” can be seen with dorsal dislocation
- Loss of bony prominence at “knuckle” with volar dislocation
- Significant hand swelling

Feel

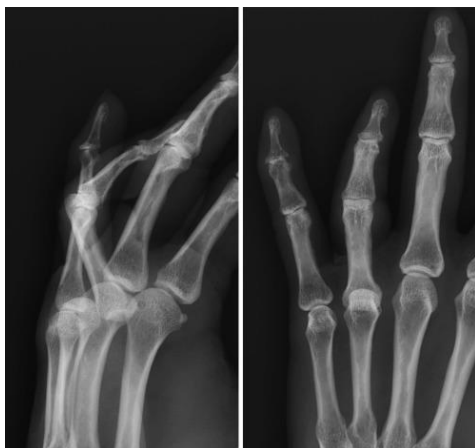- Step deformity palpable at level of MPCJ of affected digit
- Maximal tenderness at MCPJ
- Often have altered sensation to affected digit

Move

- There is no active flexion or extension at affected MCPJ
- PIPJ and DIPJ movement of affected digit is reduced due to pain and disruption of finger flexors/extensors

Radiology

Standard hand-series X-ray



X-ray showing volar MCPJ dislocation of right ring finger

<https://www.sciencedirect.com/science/article/pii/S221049171630029X>

Associated Injuries

- Usually associated with significant soft-tissue damage surrounding MCPJ
- Volar plate rupture
- MCPJ collateral ligament injury
- Fractures of proximal phalanx or metacarpal head
- Open dislocation

Emergency Management

- Analgesia
- Procedural sedation
- Closed reduction
 - For dorsal MCPJ dislocation, start with wrist and affected digit in flexion to relax finger flexors and lateral bands. Gently extend finger and simultaneously apply direct pressure over dorsal aspect of proximal phalanx until reduction achieved
 - For volar MCPJ dislocation, reduction should not be attempted in ED. These injuries are often irreducible and if performed incorrectly will convert a reducible injury to irreducible.
- Apply POSI in position of MCPJ comfort (MCPJ does NOT need to be flexed to 70 degrees)
- Repeat X-ray to assess post-reduction position and associated fractures

Disposition and Follow-up

- All MCPJ dislocations must be referred to a hand specialist for follow-up
- Volar MCPJ dislocations should be referred immediately to a hand specialist for reduction or surgical fixation.
- The majority of dorsal MCPJ dislocations are clinically unstable after reduction and will also require surgery. Dorsal MCPJ dislocations that are clinically stable typically have minor injury to the volar plate and are not associated with fractures. These can usually be managed conservatively with splinting and exercises guided by a hand therapist.

Pearls and Pitfalls

- Longitudinal traction is NOT encouraged for closed reduction of digital MCPJ dislocations as it can pull surrounding soft-tissue structures into the joint, making it irreducible
- MCPJ dislocations are major hand injuries and if inadequately managed can lead to poor functional outcomes and long-term disability

Further Reading

Borchers, J., & Best, T. (2012). Common finger fractures and dislocations. *American Family Physician*. 85(8), 805-810.

Metacarpal-Phalangeal Joint (MCPJ) Dislocation of Thumb

Definition

Dorsal or volar (rare) translation of proximal phalanx relative to first metacarpal

Mechanism

High energy trauma resulting in forceful hyperflexion or hyperextension at thumb MCPJ

Clinical Assessment

Look

- Deformity at level of thumb MCPJ
- Obvious prominence at thumb knuckle can be seen with dorsal dislocation
- Loss of bony prominence at thumb knuckle with volar dislocation
- Swollen thumb

Feel

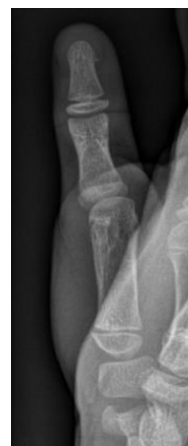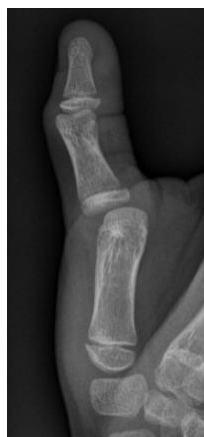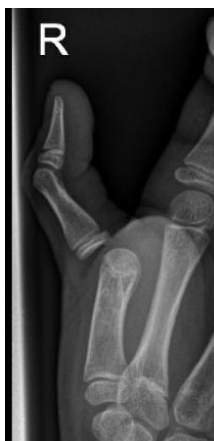- Step deformity palpable at thumb MCPJ
- Maximal tenderness at MCPJ
- Often have altered sensation to thumb

Move

- There is no active flexion or extension at thumb MCPJ
- IPJ movement is reduced due to pain

Radiology

Standard thumb series X-ray



X-ray showing dorsal MCPJ dislocation of thumb in paediatric patient

Associated Injuries

- Rupture of thumb collateral ligaments, particularly UCL
- Volar plate injury
- Fracture of proximal phalanx or metacarpal head

Emergency Management

- Analgesia
- Procedural sedation
- Closed reduction
 - For dorsal thumb MCPJ dislocation, start with wrist in slight flexion. Simultaneously apply direct pressure over dorsal aspect of proximal phalanx and gently extend thumb until reduction achieved.
 - For volar thumb MCPJ dislocation, start with wrist in slight flexion. Simultaneously apply direct pressure over volar aspect of proximal phalanx and gently flex thumb until reduction achieved.
- Apply thumb spica plaster in position of comfort and elevate
- Repeat X-ray to assess post-reduction position and associated fracture

Disposition and Follow-up

- All thumb MCPJ dislocations must be referred to a hand specialist for follow-up
- Thumb MCPJ dislocations that are clinically stable, with partial tear to UCL and no Stener lesion, and not associated with a fracture can be managed conservatively with splinting and exercises guided by a hand therapist.
- The majority of thumb MCPJ dislocations however will be clinically unstable after reduction. These will require surgery for definitive management.

Pearls and Pitfalls

- Longitudinal traction is NOT encouraged for closed reduction of thumb MCPJ dislocations as it can pull surrounding soft-tissue structures into the joint, making it irreducible. This is particularly so if the UCL has been ruptured
- Thumb MCPJ dislocations are a major injury and if inadequately managed can lead to poor functional outcomes and long-term disability

Further Reading

Borchers, J., & Best, T. (2012). Common finger fractures and dislocations. *American Family Physician*. 85(8), 805-810.

Potini, V., Sood, A., Sood, A., & Mastromonaco, E. (2014). Volar dislocation of the thumb metacarpophalangeal joint with acute repair of the ulnar collateral ligament. *Case Reports Plastic Surgery and Hand Surgery*. 1(1), 5-7.

Carpometacarpal Joint (CMCJ) Dislocation (Digits 2-5)

Definition

Dorsal or volar (rare) translation of the metacarpal relative to distal carpus

Mechanism

High energy trauma resulting in axial loading and hyperflexion or hyperextension force eg: punching a wall, falling onto hand

Clinical Assessment

Look

- Gross swelling to wrist and hand
- Deformity often obscured by swelling

Feel

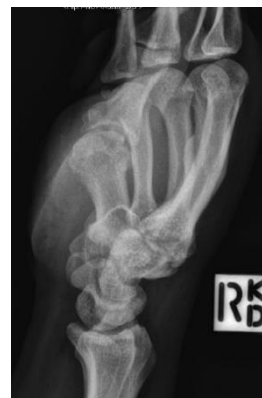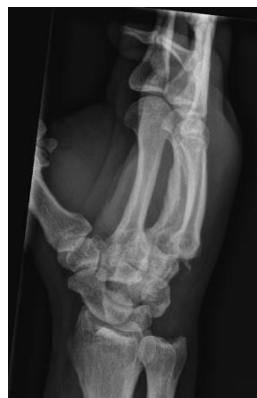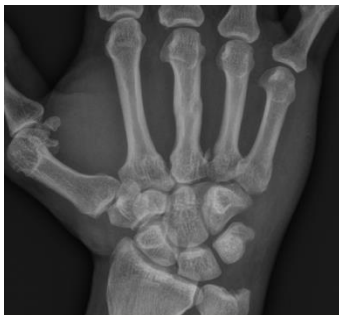- Palpable step deformity at CMCJ of affected digit, particularly with dorsal dislocation
- Maximal tenderness at CMCJ
- There may be altered sensation to palm or dorsum of hand

Move

- Wrist flexion and extension is limited by pain
- MCPJ flexion and extension of affected digit is reduced secondary to pain
- Supination and pronation of forearm is preserved

Radiology

Standard wrist-series X-ray



X-rays showing dorsal 4th CMCJ dislocation with avulsion # base of 4th metacarpal

Associated Injuries

- Often associated with metacarpal fracture
- Rupture of surrounding CMCJ ligaments

Emergency Management

- Oral analgesia
- Procedural sedation
- Closed reduction
 - For dorsal CMCJ dislocation start with arm in pronation, wrist in slight flexion and MCPJs in flexion. Apply longitudinal traction, gently extend affected metacarpal and simultaneously apply direct pressure over dorsal aspect of base of affected metacarpal until reduction achieved
 - For volar CMCJ dislocation start with forearm in neutral or supination, wrist in neutral and MCPJs in flexion. Apply longitudinal traction, gently flex affected metacarpal and simultaneously apply direct pressure over volar aspect of base of affected metacarpal until reduction achieved
- Apply short-arm backslab plaster and elevate
- Repeat X-ray to assess post-reduction position and for associated fracture

Disposition and Follow-up

- All CMCJ dislocations must be referred to a hand specialist for follow-up
- CMCJ dislocations are usually unstable following reduction and require surgery for definitive management.

Pearls and Pitfalls

- CMCJ dislocations are not always obvious on X-ray due to the overlapping of bones. Careful examination of both the oblique and lateral views are critical to diagnosing this injury.
- CMCJ dislocations of the ring and little finger are most common because of their relative mobility.

Further Reading

Jumeau, H., Lechien, P., & Dupriez, F. (2016). Conservative treatment of carpometacarpal dislocation of the three last fingers. *Case Reports in Emergency Medicine*. <https://doi.org/10.1155/2016/4962021>

Pundkare, G., & Patil, A. (2015). Carpometacarpal joint fracture dislocation of second to fifth finger. *Clinics in Orthopaedic Surgery*. 7(4), 430 – 435.

Carpometacarpal Joint (CMCJ) Dislocation of Thumb

Definition

Dorsal or volar (rare) translation of 1st metacarpal relative to trapezium

Mechanism

High energy trauma resulting in axial load or direct blow over volar or dorsal thumb web space

Clinical Assessment

Look

- Swollen hand, particularly in thenar eminence
- Clinical deformity is often obscured by swelling

Feel

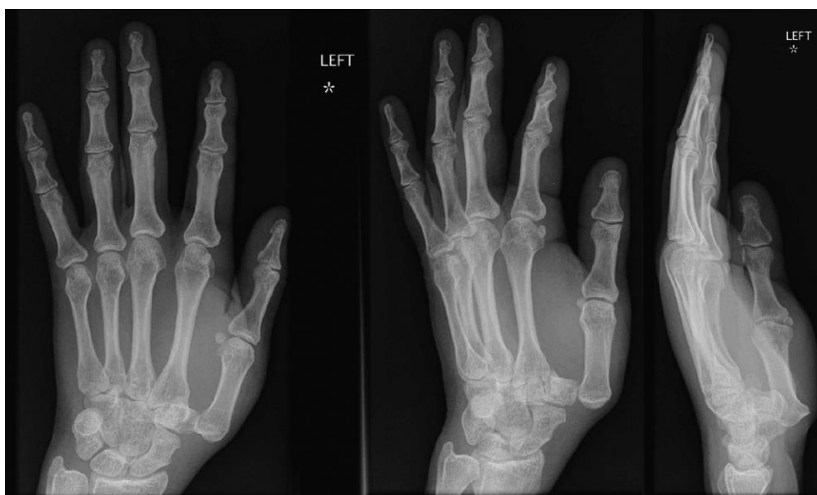- Palpable step deformity at level of thumb CMCJ
- Maximal tenderness of CMCJ
- There may be altered sensation to the thumb

Move

- Thumb opposition to little finger is key movement limited by pain
- Thumb flexion and extension is relatively preserved as this occurs at the MCPJ

Radiology

Standard thumb-series X-ray



X-rays showing volar CMCJ dislocation of left thumb

<https://www.orthobullets.com/hand/10119/thumb-cmc-dislocation>

Associated Injuries

- Rupture of CMCJ ligaments
- Fracture of 1st metacarpal or trapezium

Emergency Management

- Oral analgesia
- Procedural sedation
- Closed reduction
 - For dorsal thumb CMCJ start with wrist in flexion. Apply longitudinal traction, gently extend thumb and simultaneously apply direct pressure over dorsal base of metacarpal until reduction achieved.
 - For volar thumb CMCJ dislocation start with forearm and wrist in neutral. Apply longitudinal traction, gently flex thumb and simultaneously apply direct pressure over volar base of metacarpal until reduction achieved.
- Apply thumb spica plaster in position of comfort and elevate
- Repeat X-ray to assess post-reduction position and associated fracture

Disposition and Follow-up

- All thumb CMCJ dislocations must be referred to a hand specialist for follow-up
- CMCJ dislocations are usually unstable following reduction and require surgery for definitive management.

Pearls and Pitfalls

- Thumb CMCJ dislocations are often missed as clinical deformity is not obvious and thumb flexion and extension (which occurs at the MCPJ) is preserved.
- Assessing for thumb opposition and careful examination of thumb X-ray are both critical for diagnosing this injury
- Thumb CMCJ dislocations are a major injury and if inadequately managed can lead to osteoarthritis of the CMCJ, poor functional outcomes and long-term disability

Further Reading

Lahiji, F., Zandi, R., & Maleki, A. (2015). First carpometacarpal joint dislocation and review of literatures. *The Archives of Bone and Joint Surgery*. 3(4), 300-303.

Lunate Dislocation

Definition

Volar or dorsal (very rare) migration of lunate relative to other carpus

Mechanism

High energy fall onto outstretched or hyper-flexed wrist

Clinical Assessment

Look

- Grossly swollen wrist
- Often no obvious clinical deformity

Feel

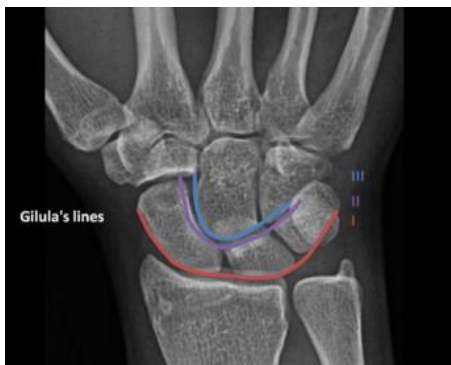- Maximal tenderness over the lunate
- Step deformity often not palpable
- May have altered sensation in median nerve distribution

Move

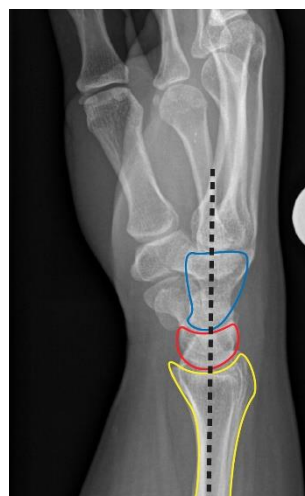- Limited wrist movement with extension particularly painful
- May have loss of motor function in median nerve distribution

Radiology

Standard wrist-series X-ray, lateral view crucial to determine direction of dislocation. In a “normal” wrist X-ray, the Gilula lines are smooth and the capitate sits squarely in the lunate “cup”

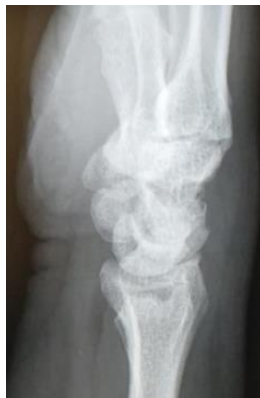
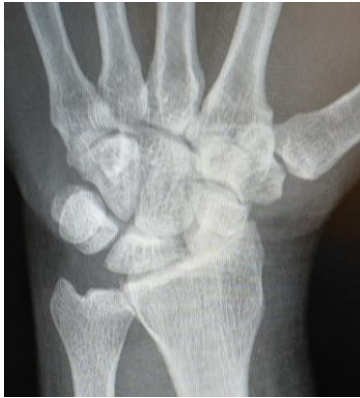
https://posterimg.netkey.at/esr/viewing/index.php?module=viewing_poster&task=viewsection&pi=136622&ti=473646&searchkey=



<http://www.emcurious.com/blog-1/2015/7/8/1ftadghymctqd2flwZ7ao4zw1m6tb>

Normal wrist X-rays with smooth Gilula lines and capitate sitting squarely in lunate “cup”



Wrist X-rays showing volar lunate dislocation – there is disruption to lunate line and the lunate has migrated in a volar direction and “tipped” over

Associated Injuries

- Median Nerve injury
- Rupture of surrounding peri-lunate ligaments
- Carpal fractures

Emergency Management

- Oral analgesia
- Procedural sedation
- Closed reduction
 - For volar lunate dislocations, bend elbow to 90 degrees and keep wrist in neutral. Apply traction/counter-traction at level of wrist. Simultaneously flex wrist and apply pressure over volar lunate until reduction is achieved
 - For dorsal lunate dislocations, bend elbow to 90 degrees and keep wrist in neutral. Apply traction/counter-traction at level of wrist. Simultaneously extend wrist and apply pressure over dorsal lunate until reduction is achieved
- Place in sandwich slab plaster and elevate
- Check integrity of median nerve
- Repeat X-ray to assess post-reduction position and assess for associated fractures

Disposition and Follow-up

- All lunate dislocations require immediate referral to hand surgeon and surgical fixation for definitive management
- Urgent surgical intervention is required for cases of failed reduction with median nerve compromise

Pearls and Pitfalls

- Rare injury with catastrophic consequences if missed and is inherently unstable after closed reduction
- Different to peri-lunate dislocation (lateral X-ray view essential for differentiating)
- The degree of volar lunate displacement and rotation can vary and does not have to be complete “spilled-cup” to be considered lunate dislocation
- Dorsal lunate dislocation is very rare and almost always occurs with concomitant carpal fractures

Further Reading

Boggess, BR. (2019). Evaluation of the adult with acute wrist pain in *Uptodate*.

Goodman, A. D., Harris, A. P., Gil, J. A., Park, J., Raducha, J., & Got, C. J. (2019). Evaluation, management, and outcomes of lunate and perilunate dislocations. *Orthopedics (Online)*, 42(1), 1-6.

Peri-lunate Dislocation

Definition

Dorsal or volar (very rare) migration of capitate relative to lunate

Mechanism

High energy fall onto extended or hyper-flexed wrist

Clinical Assessment

Look

- Grossly swollen wrist
- There may be clinical deformity over dorsal wrist if dorsal peri-lunate dislocation

Feel

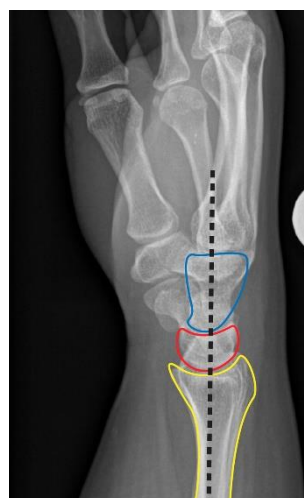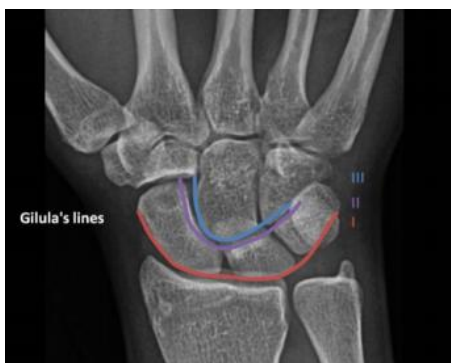- Maximal tenderness at inter-carpal joint between capitate and lunate
- May have altered sensation in median nerve distribution

Move

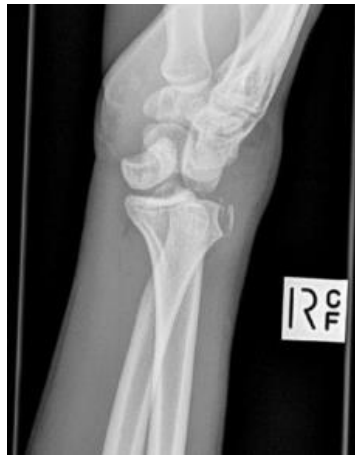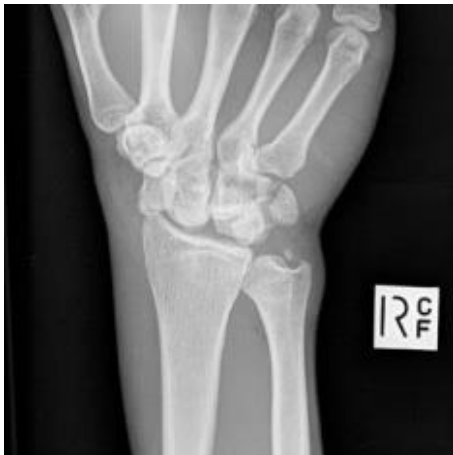- Limited wrist movement due to pain
- Difficulty making a fist
- May have loss of motor function in median nerve distribution

Radiology

Standard wrist-series X-ray, lateral view crucial to determine direction of dislocation. In a “normal” wrist X-ray, the Gilula lines are smooth and the capitate sits squarely in the lunate “cup”



Normal wrist X-rays with smooth Gilula lines and capitate sitting squarely in lunate “cup”



X-ray showing dorsal peri-lunate dislocation with disruption to both II and III Gilula line and dorsal displacement of capitate relative to lunate cup

Associated Injuries

- Median nerve injury
- Carpal fractures – scaphoid fracture most common
- Rupture of surround inter-carpal ligaments

Emergency Management

- Oral analgesia
- Procedural sedation
- Closed reduction
 - For dorsal peri-lunate dislocation flex elbow to 90 degrees and wrist in neutral. Apply traction/counter-traction at level of mid-carpal joint. Simultaneously extend wrist and apply direct pressure over dorsal capitate until reduction achieved.
 - For volar per-lunate dislocation flex elbow to 90 degrees and wrist in neutral. Apply traction/counter-traction at level of mid-carpal joint. Simultaneously flex wrist and apply direct pressure over volar capitate until reduction achieved
- Place in sandwich slab plaster and elevate
- Check integrity of median nerve
- Repeat X-ray to assess post-reduction position

Disposition and Follow-up

- All peri-lunate dislocations require immediate referral to hand specialist and surgical fixation for definitive management
- Urgent surgical intervention is required for cases of failed reduction with median nerve compromise

Pearls and Pitfalls

- Different to lunate dislocation (lateral X-ray view essential for differentiating)
- Inherently unstable after closed reduction and requires surgery for definitive management
- Volar peri-lunate dislocations are rare and always occurs with concomitant carpal fractures

Further Reading

Apergis, E. (2013) Acute Perilunate Dislocations and Fracture-Dislocations. In: Fracture-Dislocations of the Wrist. Springer, Milano

Boggess, B. (2019). Evaluation of the adult with acute wrist pain in *Uptodate*.

Goodman, A., Harris, A., Gil, J., Park, J., Raducha, J., & Got, C. (2019). Evaluation, management, and outcomes of lunate and perilunate dislocations. *Orthopedics (Online)*, 42(1), 1-6.

Deep Palmar Space Infections

Definition

Infection of the deep fascial spaces of the hand

Can be thenar, mid-palmar or hypothenar space

Mechanism

Deep inoculation due to trauma (most common)

Secondary to spread from superficial infections

Hematogenous spread

Clinical Assessment

Look

- Focal palmar swelling with erythema
- Fingers and thumb may be in partially flexed posture due to swelling
- May be overlying wounds or discharge, particularly with penetrating injuries

Feel

- Extremely tender, particularly over the anatomically affected fascial space on palmar side of hand

Move

- Pain with active thumb and finger flexion, particularly for thenar and mid-palmar space infections
- Pain with passive thumb and finger extension, particularly for thenar and mid-palmar space infections.

Radiology

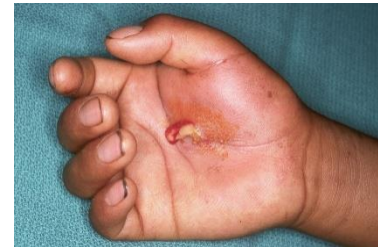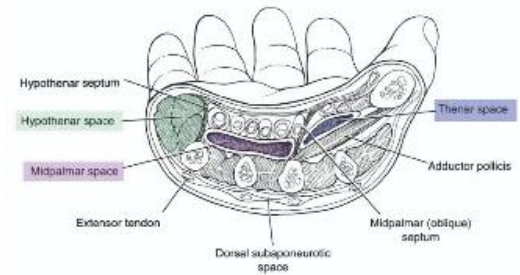
Standard hand-series X-ray to rule out presence of foreign body and assess for bony involvement, particularly with penetrating injuries.

Ultrasound can be considered to assess for evidence of an abscess

Consider blood tests for inflammatory markers

Differentials

- Gout
- Superficial infections such as cellulitis
- Necrotising fasciitis
- Arthritis including septic and rheumatoid



<https://www.orthobullets.com/hand/6106/deep-space-and-collar-button-infections>

Emergency Management

- Analgesia
- Empiric IV antibiotics – consider first generation cephalosporin eg: cephazolin
- ADT
- POSI plaster and elevate

Disposition and Follow-up

- All deep palmar space infections are surgical emergencies and must be referred immediately to a hand specialist
- Delay in surgery can result in systemic sepsis, necrosis and long-term functional loss

Pearls and Pitfalls

- Focal tenderness on palpation is key to differentiating which of the three deep fascial spaces are infected

Further Reading

Teo, W., & Chung, K. (2019). Hand infections. *Clinics in Plastic Surgery*. 46(3), 371-381

Muttath, S., & Chung, K. (2018). Overview of hand injections in *UpToDate*.

Felon

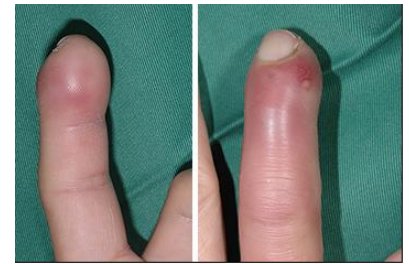Definition

Subcutaneous abscess of the pulp space of digit

Mechanism

Most commonly secondary to penetrating injury or untreated paronychia

Idiopathic onset



Overview of Hand Injuries, Muttath et al. UpToDate

Clinical Assessment

Look

- Localised swelling and erythema around distal phalanx, particularly over pulp
- There may be an area of imminent rupture

Feel

- Warm and extremely tender over pulp
- Fluctuant swelling to pulp

Move

- May have reduced DIPJ range due to pain

Investigations

Standard finger series X-ray to assess for foreign body

Consider blood tests for inflammatory markers

Differentials

- Gouty tophi
- Metastatic lesions
- Paronychia

Emergency Management

- Oral analgesia or ring block after examination
- Empiric IV antibiotics - consider first generation cephalosporin eg: cephazolin
- Dorsal finger splint for comfort and strict elevation. Beware to not apply tape too tightly and risk causing digital ischaemia



Disposition and Follow-up

- Whilst some early presentations may be adequately managed with warm-water soaks, elevation and antibiotics, majority will require surgical debridement and should be referred to a hand specialist for follow-up

Pearls and Pitfalls

- Beware foreign body trapping – finger-series X-ray crucial part of assessment
- Can be resistant to conservative therapy due to complex anatomy of fibrous septae in pulp space. If managing conservatively, must be reviewed by GP within 24 hours to ensure therapy is effective
- If not adequately managed, can progress into osteomyelitis, flexor tenosynovitis, pressure associated ischaemia and septic arthritis

Further Reading

Franko, O., & Abrams, R. (2013). Hand infections. *Orthopaedic Clinics of North America*. 44(4), 625-634.

Koshy, J., & Bell, B. (2019). Hand infections. *Journal of Hand Surgery America*. 44(1), 46-54

Muttath, S., Chung, K., & Ono, S. (2018). Overview of Hand Injuries in *UpToDate*

Tannan, S., & Deal, D. (2012). Diagnosis and management of the acute felon: evidence-based review. *Journal of Hand Surgery America*. 37(12), 2603-2604.

High Pressure Injection Injury

Definition

Accidental injection of industrial substance into hand at high-pressures causing significant tissue trauma

Mechanism

Most often caused by high pressure industrial equipment such as spray-paint guns

Clinical Assessment

Look

- Initially can be benign appearance with minimal swelling and erythema
- There is always a site of entry, typically a puncture-type wound

Feel

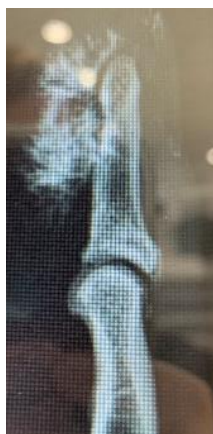- Palpable swelling
- May be crepitus if air injected
- May have reduced sensation to touch and may have reduced capillary refill time

Move

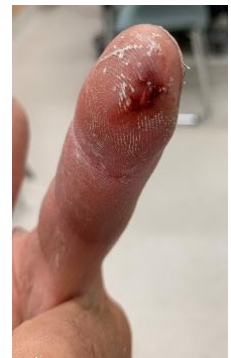- Finger movement usually preserved in acute stage

Radiology

Finger series X-ray essential to assess for presence and extent of foreign material, and subcutaneous emphysema



Lateral finger X-ray showing presence of foreign material over volar distal phalanx



Associated Injuries

Can be associated with systemic effects depending on nature of injected toxin

Emergency Management

- Oral analgesia
- Avoid ring-block as this can increase pressure inside digit
- Broad spectrum IV antibiotics – consider discussing with hands or plastics registrar
- ADT
- Digital splint and elevate. Beware to not apply tape too tightly and risk causing digital ischaemia.



Disposition and Follow-up

- This is a surgical emergency and must be referred immediately to a hand specialist
- Delay in surgery can result in catastrophic outcomes with compartment syndrome and gross necrosis requiring amputation

Pearls and Pitfalls

- Initial presentation is usually benign and mistaken for minor injury. Symptoms often manifest after 4-6 hours.
- High index suspicion if presence of puncture wounds is associated with history of being near jet stream or use of high-pressure industrial equipment.
- Look for evidence of foreign material on X-ray eg: soft-tissue densities or lucency can represent paint or grease

Further Reading

Amsdell, S., & Hammert, W. (2013). High-pressure injection injuries in the hand: current treatment concepts. *Plastic and Reconstructive Surgery*. 132(4), 586e-591e.

Cannon, T. (2016). High-pressure injection injuries of the hand. *Orthopaedic Clinics of North America*. 47(3), 617-624.

Hogan, C., & Ruland, R. (2006). High-pressure injection injuries to the upper extremity: a review of the literature. *Journal of Orthopaedic Trauma*. 20(7), 503-511.

Infectious Flexor Tenosynovitis

Definition

Infection of flexor tendons and synovial sheath in either hand or fingers

Mechanism

Direct introduction of pathogen through trauma (eg: animal bite)

Secondary to spread from superficial infections

Haematogenous spread

Clinical Assessment

Look

- Fusiform swelling over affected finger with associated erythema
- Digit often held in flexion at rest
- There may be evidence of puncture wound

Feel

- Maximal tenderness along affected tendon
- Warm to touch along affected digit

Move

- Most painful with passive extension of affected digit
- Active flexion of affected digit reproduces moderate pain

Radiology

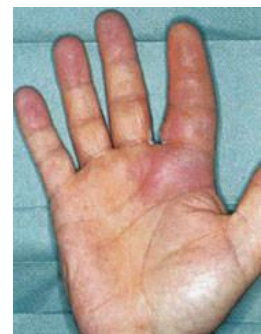Standard hand-series X-ray to rule out foreign body and bony involvement in cases of puncture wound

Differentials

- Chronic inflammatory tenosynovitis
- Cellulitis
- Gout
- Arthritis including rheumatoid and septic

Emergency Management

- Analgesia
- Empiric IV antibiotics
- POSI plaster and elevate



*Pyogenic Flexor Tenosynovitis. R. Yoon. Orthobullets.
<https://www.orthobullets.com/hand/6105/pyogenic-flexor-tenosynovitis>*

Disposition and Follow-up

- All suspected infectious tenosynovitis should be referred immediately to a hand specialist and most will require surgical management.
- Untreated infectious tenosynovitis can lead to systematic sepsis, permanent destruction to tendon, compartment syndrome and poor functional outcomes

Pearls and Pitfalls

- Most commonly mistaken for chronic inflammatory tenosynovitis which is common in patients with rheumatoid arthritis. Key differential is history of trauma or recent infection
- Diabetes, IVDU and being immunocompromised are risk factors for infectious tenosynovitis
- Consider blood tests as part of work-up, and blood cultures if fever or systemic signs of infection

Further Reading

Giladi, A., Malay, S., & Chung, K. (2015). A systematic review of the management of acute pyogenic flexor tenosynovitis. *Journal of Hand Surgery European Volume*. 40(7), 720-728.

Koshy, J., & Bell, B. (2019). Hand infections. *Journal of Hand Surgery America*. 44(1), 46-54

Sexton, D., & Leversedge, F. (2018) Infectious tenosynovitis in *UpToDate*.

Teo, W., & Chung, K. (2019). Hand infections. *Clinics in Plastic Surgery*. 46(3), 371-381

Paronychia

Definition

Inflammation of the skin folds surrounding nail

Mechanism

Usually infective or irritant aetiology (eg: chemotherapeutics)

Can be precipitated by local trauma to digit

Clinical Assessment

Look

- Swollen and erythematous fingertip
- Can be associated with superficial abscess, usually between nail plate and nail fold

Feel

- Warm and tender to touch
- Fluctuant swelling

Move

- Digital pressure test to volar aspect of affected fingertip. Blanching of skin folds at affected area indicates presence of abscess
- May have reduced DIPJ range due to pain and swelling

Radiology

Imaging is not usually indicated unless suspicious of deeper infection

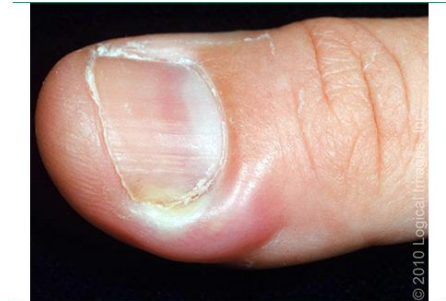Differentials

- Felon
- Herpetic Whitlow
- Onychomycosis
- Green nail syndrome

Emergency Management

Without abscess

- Apply topical antibiotics (eg: bactroban) and warm water soaks
- Consider systemic oral antibiotics for resistant infection



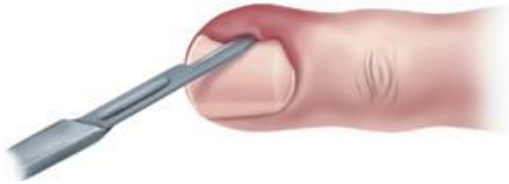Swelling, erythema, and a purulent collection are present in this patient with acute paronychia.

Reproduced with permission from: www.visualdx.com. Copyright VisualDx. All rights reserved.

Graphic 70107 Version 6.0

With abscess

- Ring block then insertion of scalpel under cuticle margin and nail fold to express pus



<https://www.aafp.org/afp/2001/0315/p1113.html>

- Follow with warm water soaks
- Consider systemic oral antibiotics

Disposition and Follow-up

- Can be followed-up with GP and should be reviewed within 48hours to ensure therapy effective

Pearls and Pitfalls

- If left untreated simple paronychia can progress to abscess
- Pus culture may be considered to guide antimicrobial therapy in resistant cases

Further Reading

Franko, O., & Abrams, R. (2013). Hand infections. *Orthopaedic Clinics of North America*. 44(4), 625-634.

Koshy, J., & Bell, B. (2019). Hand infections. *Journal of Hand Surgery America*. 44(1), 46-54

Leggit, J. (2017). Acute and chronic paronychia. *American Family Physician*. 96(1), 44-51.

Goldstein, B., & Goldstein, A. (2019). Paronychia in *UpToDate*