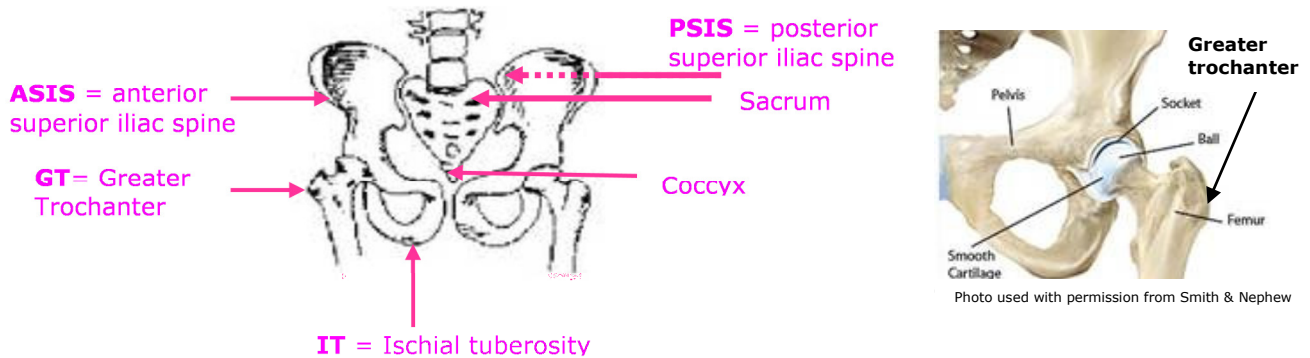




**Spinal Seating Professional Development Project
Assessment Form RD4.1: Initial Interview**

Handy tips for finding key bony landmarks

Pelvis:



Find these on yourself or practice these with a colleague.

Anterior superior iliac spine (ASIS)

- Put your hand on the hips
- locate the Iliac Crest / hip bone palpate frontward
- ASIS is a sharp notch:, above the femur/ thigh bone when seated.

Posterior superior iliac spine (PSIS)

- The "dimples" between the buttocks and waist
- Put your hand on the hips
- Locate the Iliac Crest / hip bone and palpate backward
- PSIS is less pronounced but has no muscle over it

Ischial tuberosity (IT)

- The IT is located only about 5cm from midline, slip you hand right under your buttock and towards the midline
- Sit on your hand with palm up to feel the IT against your fingers tips.
- When you assess others, wear a slippery glove / plastic bag to reduce friction as you slide you hand under the buttock. If you squat down to level your shoulder with the cushion, you will gain more leverage to get your hand under.
- If the client is sitting with posterior pelvic tilt (slouching), the ITs will be moved forward, away from backrest.
- If the client is sitting with anterior pelvic tilt (arching the back), the ITs will be pointing backwards toward the backrest.

Greater trochanter (GT)

- Using the ball of your palm, rub along the lateral aspect of the thigh, back and forth between mid-thigh and pelvis to find a bony notch.