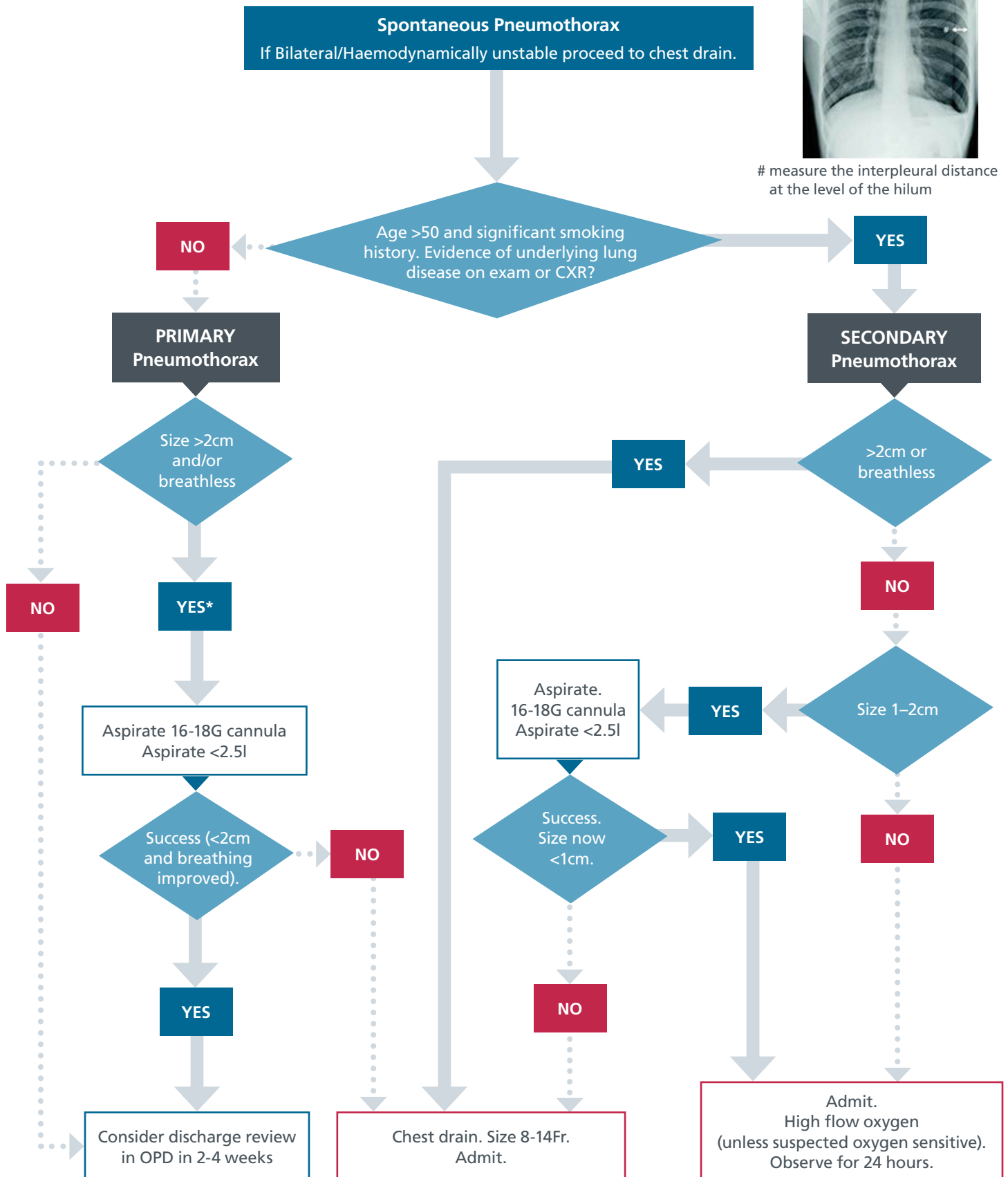




measure the interpleural distance at the level of the hilum



* In some patients with a large pneumothorax but minimal symptoms conservative management may be appropriate.