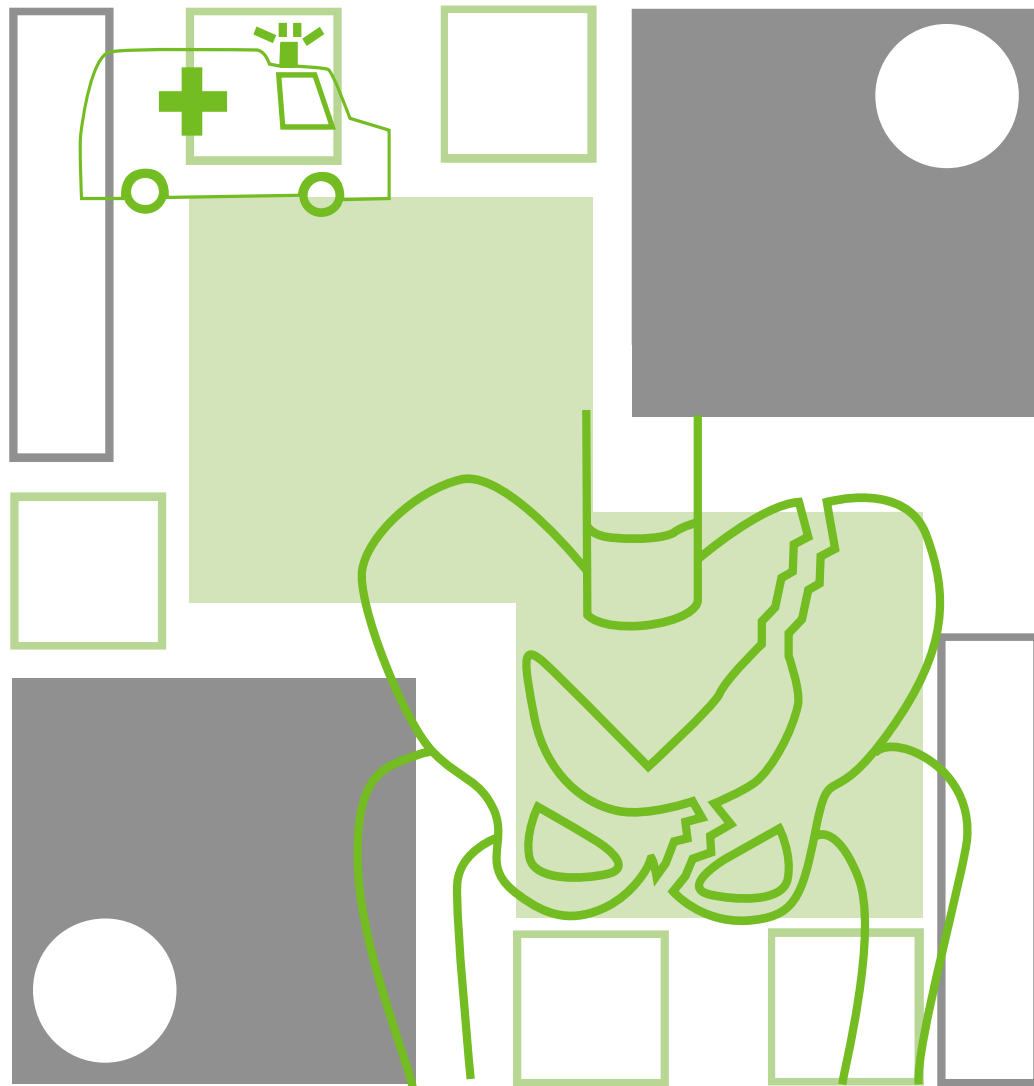


# ■ ■ Management of haemodynamically unstable patients with a Pelvic Fracture



**Suggested citation:**

Dr Martin Heetveld 2007, *The Management of Haemodynamically Unstable Patients with a Pelvic Fracture*, NSW Institute of Trauma and Injury Management.

Author

Dr Martin Heetveld, Trauma Fellow, Trauma Service, Liverpool Hospital

Editorial team

NSW ITIM Clinical Guidelines Committee

Dr Ian Harris, Director of Orthopaedics, Liverpool Hospital

Ms Kathleen Peters (RN), Case Manager, Trauma Service, Liverpool Hospital

Dr Glen Schlaphoff, Director of Radiology, Liverpool Hospital

Assoc. Prof. Michael Sugrue, Trauma Director, Trauma Service, Liverpool Hospital

Ms Joan Lynch (RN), Project Manager, Trauma Service, Liverpool Hospital

Mr Glenn Sisson (RN), Trauma Clinical Education Manager, NSW ITIM

This work is copyright. It may be reproduced in whole or in part for study training purposes subject to the inclusion of an acknowledgement of the source. It may not be reproduced for commercial usage or sale. Reproduction for purposes other than those indicated above requires written permission from the NSW Institute of Trauma and Injury Management.

© NSW Institute of Trauma and Injury Management

SHPN (TI) 070026

ISBN 978-1-74187-143-5

For further copies contact:

**NSW Institute of Trauma and Injury Management**

PO Box 6314, North Ryde, NSW 2113

Ph: (02) 9887 5726

or can be downloaded from the NSW ITIM website

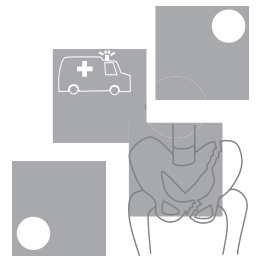
<http://www.itim.nsw.gov.au>

or the

NSW Health website <http://www.health.nsw.gov.au>

January 2007

# Important notice!



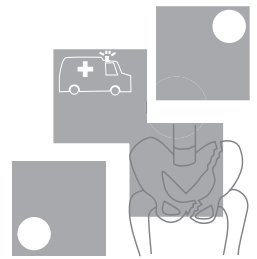
*'The Management of Haemodynamically Unstable Patients with a Pelvic Fracture'* clinical practice guidelines are aimed at assisting clinicians in informed medical decision-making. They are not intended to replace decision-making. The authors appreciate the heterogeneity of the patient population and the signs and symptoms they may present with and the need to often modify management in light of a patient's co-morbidities. The guidelines are intended to provide a general guide to the management of specified injuries. The guidelines are not a definitive statement on the correct procedures, rather they constitute a general guide to be followed subject to the clinicians judgement in each case. The information provided is based on the best available information at the time of writing, which is December 2003. These guidelines will therefore be updated every five years and consider new evidence as it becomes available.

## **These guidelines are intended for use in adults only.**

All guidelines regarding pre-hospital care should be read and considered in conjunction with NSW Ambulance Service protocols.



# Contents



**Algorithm 1 ::**  
Management of the Haemodynamically Unstable Patient with a Pelvic Fracture with Angiography Services available.....1

**Algorithm 2 ::**  
Management of the Haemodynamically Unstable Patient with a Pelvic Fracture without Angiography Services available .....2

Summary of guidelines.....3

How to determine the source of bleeding in haemodynamically unstable pelvic fracture patients? .....3

How to control pelvic bleeding with or without associated intraabdominal bleeding? .....4

What is the optimal angiography and embolisation technique?.....5

How to optimally mechanically stabilise the pelvis? ...6

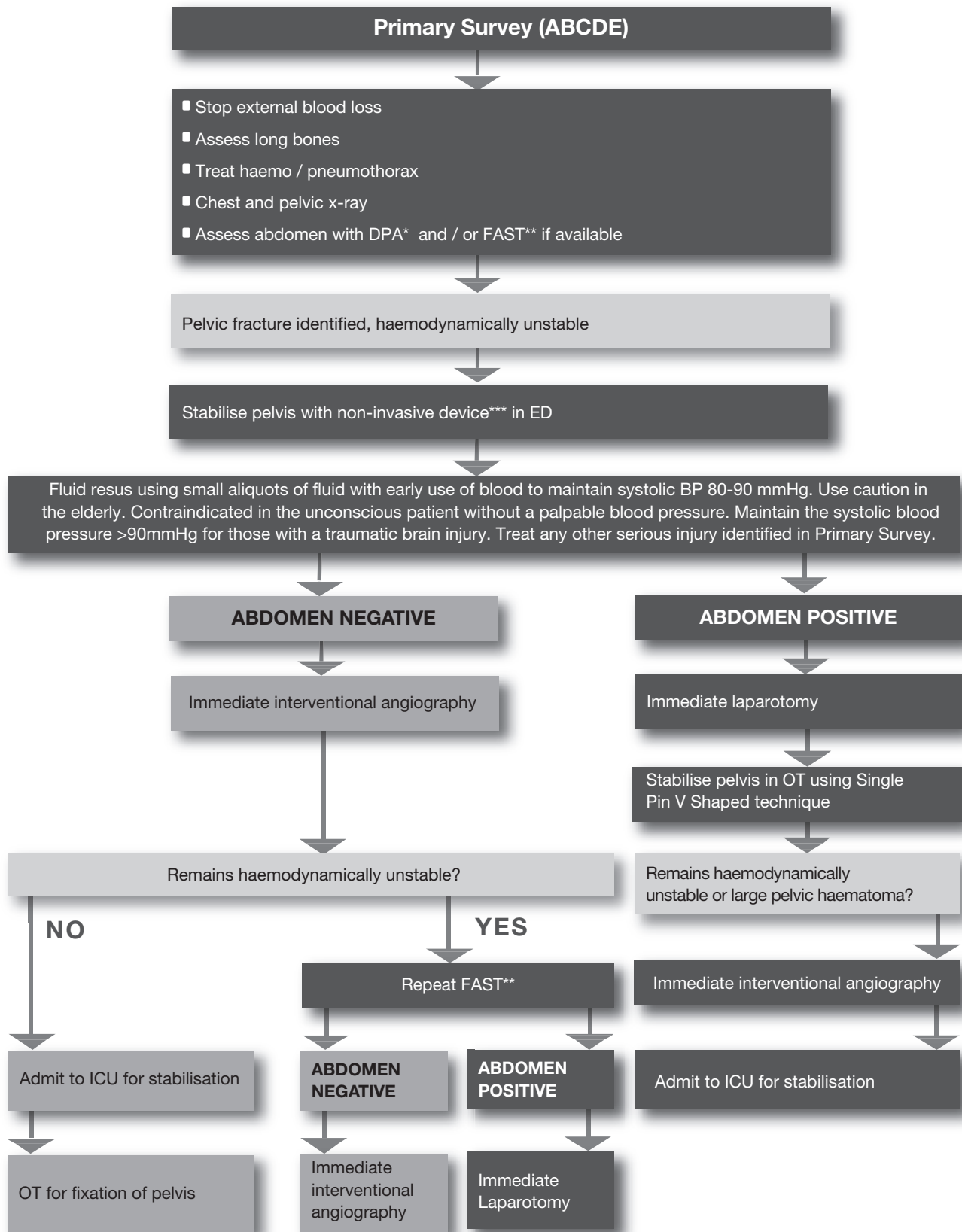
## Appendices

Appendix A ::  
Pelvic sheeting.....7



**Algorithm 1 :: Management of the Haemodynamically Unstable Patient with a Pelvic Fracture with Angiography Services available**

Management of the Haemodynamically Unstable Patient with a Pelvic Fracture **with** Angiography Services available

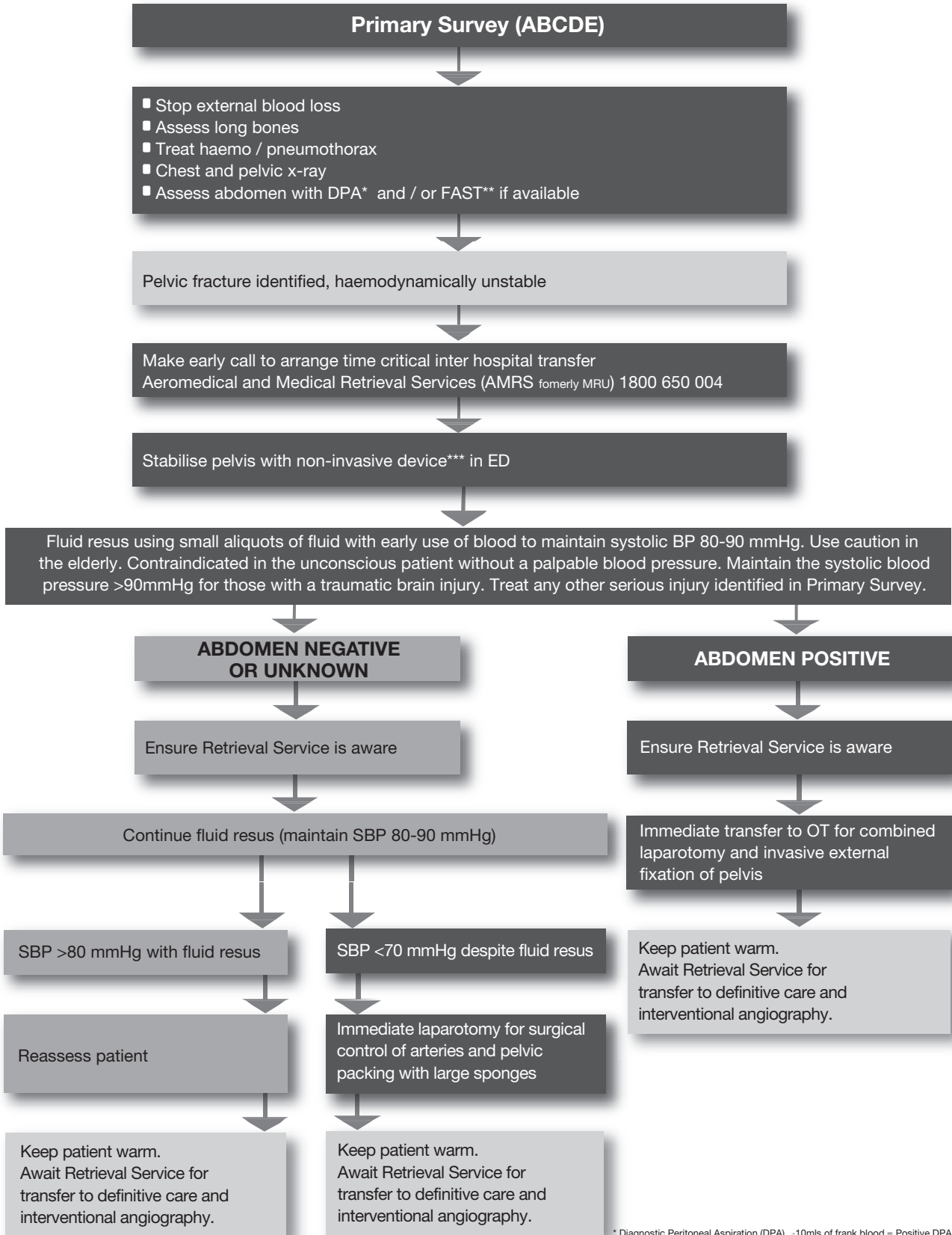


NSW Institute of Trauma and Injury Management © January 2007 - SHPN: (T) 070935

\* Diagnostic Peritoneal Aspiration (DPA) >10mls of frank blood = Positive DPA  
 \*\* Focused Abdominal Sonography in Trauma (FAST). Free fluid = Positive FAST.  
 \*\*\*Non-invasive pelvic stabilisation with sheet or binder.

**Algorithm 2 :: Management of the Haemodynamically Unstable Patient with a Pelvic Fracture without Angiography Services available**

Management of the Haemodynamically Unstable Patient with a Pelvic Fracture **without** Angiography Services available



NSW Institute of Trauma and Injury Management © January 2007. SHPN: (TI) 070036

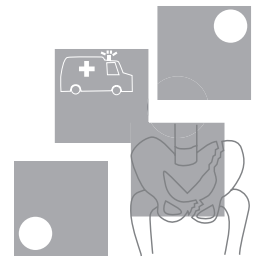
\* Diagnostic Peritoneal Aspiration (DPA) -10mls of frank blood = Positive DPA

\*\* Focused Abdominal Sonography in Trauma (FAST). Free fluid = Positive FAST.

\*\*\*Non-invasive pelvic stabilisation with sheet or binder.



# Summary of guidelines



How to determine the source of bleeding in haemodynamically unstable pelvic fracture patients?

GUIDELINE	LEVEL OF EVIDENCE
<p>When the haemodynamically unstable patient enters the resuscitation room, a primary survey with full exposure takes place. Carefully inspect for external bleeding sources and examine the long bones. A supine chest x-ray and pelvic X-ray must be obtained within ten minutes of arrival. The CXR will identify a large haemothorax. If the pelvic x-ray shows a pelvic fracture, the remaining two sites of significant bleeding are the abdomen and the pelvic retroperitoneum.</p>	<p>III-3</p>
<p>The probability of associated intraabdominal bleeding with a major pelvic fracture is 32%. The options for assessing intraabdominal bleeding are: Diagnostic Peritoneal Aspiration (DPA) and / or Focused Abdominal Sonography in Trauma (FAST). Both should be completed within 30 minutes of the patient's arrival.</p>	<p>III-3</p>
<p>DPA is a reliable diagnostic test for determining frank blood in the abdominal cavity. The aspiration is positive in the presence of &gt;10 ml of frank blood.</p>	<p>III-3</p>
<p>FAST is a good alternative diagnostic modality for evaluating free fluid in the presence of a pelvic fracture. Most frequently FAST is positive in the right upper quadrant. The suprapubic view is unreliable in pelvic fracture patients. If practical, FAST should be repeated to increase sensitivity.</p>	<p>III-2</p>
<p>When external sources, long bones, intrathoracic injury and intra-abdominal injury do not account for the hypotension in a haemodynamically unstable patient with a major pelvic fracture, pelvic arterial bleeding must be evaluated. The patient should go for immediate angiography.</p>	<p>III-3</p>
<p>In the presence of a pelvic fracture and haemodynamic instability, pelvic arterial bleeding must be evaluated even if other sources of haemorrhage have been identified.</p>	<p>IV</p>
<p>In the rural or urban environment where DPA or FAST is not available, identification of the source of bleeding is reliant on the method of exclusion. Upon exclusion of the other four sources of bleeding and in light of continuing haemodynamic instability it must be assumed that the patient has intraabdominal bleeding until proven otherwise.</p>	<p>Consensus</p>

How to control pelvic bleeding with or without associated intraabdominal bleeding?

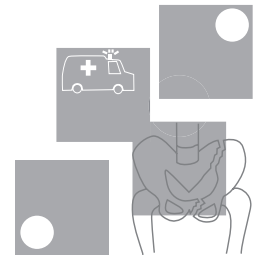
GUIDELINE	LEVEL OF EVIDENCE
<p>If intra-abdominal bleeding has been excluded by DPA and / or FAST, immediate angiography and embolisation is warranted. Transfer to the angiography suite should take place within 45 minutes of the patient's arrival. Close monitoring, ongoing resuscitation and re-assessment of an intra-abdominal bleeding source utilising FAST and / or clinical parameters are mandatory in the angiography suite.</p>	<p>III-3</p>
<p>Haemodynamically unstable patients with pelvic fractures should be managed with early non-invasive external stabilisation to aid in controlling small venous and cancellous bone bleeding. In the case of a vertical shear type pelvic fracture, supplementary femoral pin traction is necessary on the affected side. External stabilisation does not control arterial bleeding.</p>	<p>III-1</p>
<p>If laparotomy is warranted, a non-invasive or invasive external stabilisation device should be placed concomitantly with laparotomy in the operating theatre. If angiography is warranted, a non-invasive external stabilisation device should be placed prior to transfer in the resuscitation room.</p>	<p>IV</p>
<p>If intra-abdominal bleeding has been determined by DPA and / or FAST, immediate laparotomy is warranted. Concomitant intestinal perforation should be dealt with in a damage control fashion if necessary.</p>	<p>III-3</p>
<p>If at laparotomy, performed for intraabdominal haemorrhage, there is a freely bleeding ruptured pelvic haematoma, packing and immediate transfer to angiography is preferable. Where angiography is not available or the patient is too unstable (blood pressure unable to be restored above 70 mmHg), the haematoma should be evacuated, the internal iliac arteries bilaterally ligated and the pelvis packed.</p>	<p>IV</p>
<p>In the situation of exsanguination at presentation, with little or no response to fluid resuscitation, immediate operation is the only life saving option: Laparotomy with surgical ligation of bleeding arteries, pelvic packing with large sponges and stabilisation of the pelvis.</p>	<p>IV</p>
<p>Internal fixation of major pelvic fractures is contra-indicated in haemodynamically unstable patients.</p>	<p>IV</p>
<p>In the situation where angiography services are not available, management is determined by the degree of haemodynamic instability. In the presence of reasonable haemodynamic stability (SBP&gt;80mmhg), the pelvis should be non-invasively externally stabilised and Retrieval Services should be contacted as a matter of urgency. If the systolic blood pressure drops below 80-90mmHg, small aliquots of fluid (100-200mls) may administered. If the blood pressure becomes increasingly unstable (SBP&lt;80mmHg) and cannot be maintained with small boluses of fluid, immediate laparotomy with surgical ligation of bleeding arteries, pelvic packing with large sponges and invasive external stabilisation of the pelvis is the only life saving option available. An unstable patient should not be transferred where surgical services are available until surgical haemostasis has been achieved.</p>	<p>Consensus</p>

What is the optimal angiography and embolisation technique?

GUIDELINE	LEVEL OF EVIDENCE
<p>If a major pelvic fracture is seen on the initial pelvic x-ray in the haemodynamically unstable patient, the interventional radiologist and nursing staff should be notified immediately. It is critically important that the general surgeon coordinates care between emergency clinicians, interventional radiologist, orthopaedic surgeon, intensive care specialist, nursing and blood bank.</p>	<p>IV</p>
<p>Angiography should be performed as soon as the abdomen has been cleared as a source of bleeding or within 90 minutes of presentation. A femoral approach is preferred, but a left brachial puncture may be needed in patients in which femoral approach fails.</p>	<p>IV</p>
<p>Using 4 or 5 Fr catheters, angiography begins with a midstream abdominal flush to reassess any abdominal bleeding. A pelvis flush is then performed at aortic bifurcation level. An arterial haemorrhage requiring embolisation should present itself at the pelvis midstream flush.</p>	<p>III-3</p>
<p>Any sites of contrast extravasation, false aneurysms and occlusion of the mainstem internal iliac artery warrant embolisation. Vasospasm due to major haemorrhage may obscure bleeding distal to the spasm.</p>	<p>IV</p>
<p>Non-selective embolisation of main arteries, such as the internal iliac arteries or their first divisional branches should be performed with steel coils. Steel coils are also preferred for selective embolisation of bleeding branches. In patients with multiple distal, small branch bleeding sites a shower of gelfoam slurry can be utilised.</p>	<p>IV</p>
<p>Selective embolisation of smaller branches should be used judiciously. If respiratory or hemodynamic instability increases during angiography, non-selective bilateral embolisation of the internal iliac arteries with steel coils should be performed. Complete occlusion of the internal iliac artery is an acceptable alternative to exsanguination.</p>	<p>IV</p>
<p>Once a vessel is embolised for distal branch extravasation, the potential collateral vessels of both internal iliac arteries should be evaluated to identify additional supply to the injured vascular bed. Completion angiography is necessary to document cessation of bleeding.</p>	<p>IV</p>

## How to optimally mechanically stabilise the pelvis?

GUIDELINE	LEVEL OF EVIDENCE
<p>Rotationally unstable APC types II and III, LC type III pelvic fractures benefit most from external stabilisation. If vertical instability is also present, such as in VS and combination type pelvic fractures, rotational stabilisation needs to be supplemented by skeletal traction on the injured side.</p>	<p>III-3</p>
<p>The optimal time-effective and safe pelvic external stabilisation device in the haemodynamically unstable patient is non-invasive. A bed sheet wrapped and clamped tightly around the pelvis is a good option. There are a variety of non-invasive proprietary devices available. The device should be applied so that it allows both laparotomy access and femoral artery access for angiography.</p>	<p>IV</p>
<p>Invasive anterior external fixation devices for rotational stabilisation should only be applied when non-invasive devices fail, interfere with procedures or if more time is needed until definitive internal fixation.</p>	<p>IV</p>
<p>The simplest effective form of invasive anterior external fixation consists of a single 5-mm Schantz pin on each side, connected to two radiolucent bridging bars in a triangular construct or a single radiolucent curved rod. The apex of the triangle or top of the curve of should be placed inferiorly in the midline of the pelvis, allowing laparotomy access and the patient to sit up.</p>	<p>III-3</p>



# Pelvic sheeting

For rotationally unstable pelvic fractures: Open-book, Vertical Shear, Lateral Compression type III or Combined Mechanism fractures

**1**

Place folded bed sheet underneath the patient between iliac crests and greater trochanters.



**2**

With two trauma team members cross the sheet across the symphysis and pull the sheet firmly so it tightly fits around and stabilises the pelvis.



**3**

A third person should clamp the sheet at the four points shown (away from laparotomy / angiograph access points).



